Clinical Cancer Research

The Progress and Promise of Molecular Imaging Probes in Oncologic Drug Development

Gary J. Kelloff, Kenneth A. Krohn, Steven M. Larson, et al.

Clin Cancer Res 2005;11:7967-7985.

Updated version	Access the most recent version of this article at: http://clincancerres.aacrjournals.org/content/11/22/7967

Cited Articles	This article cites by 172 articles, 65 of which you can access for free at: http://clincancerres.aacrjournals.org/content/11/22/7967.full.html#ref-list-1
Citing articles	This article has been cited by 28 HighWire-hosted articles. Access the articles at: http://clincancerres.aacrjournals.org/content/11/22/7967.full.html#related-urls

E-mail alerts	Sign up to receive free email-alerts related to this article or journal.
Reprints and Subscriptions	To order reprints of this article or to subscribe to the journal, contact the AACR Publications Department at pubs@aacr.org.
Permissions	To request permission to re-use all or part of this article, contact the AACR Publications Department at permissions@aacr.org.

Downloaded from clincancerres.aacrjournals.org on April 5, 2013. © 2005 American Association for Cancer Research.

The Progress and Promise of Molecular Imaging Probes in Oncologic Drug Development

Gary J. Kelloff,[1] Kenneth A. Krohn,[3] Steven M. Larson,[4] Ralph Weissleder,[5] David A. Mankoff,[3] John M. Hoffman,[1] Jeanne M. Link,[3] Kathryn Z. Guyton,[6] William C. Eckelman,[2] Howard I. Scher,[4] Joyce O'Shaughnessy,[7] Bruce D. Cheson,[8] Caroline C. Sigman,[6] James L. Tatum,[1] George Q. Mills,[9] Daniel C. Sullivan,[1] and Janet Woodcock[10]

Abstract As addressed by the recent Food and Drug Administration Critical Path Initiative, tools are urgently needed to increase the speed, efficiency, and cost-effectiveness of drug development for cancer and other diseases. Molecular imaging probes developed based on recent scientific advances have great potential as oncologic drug development tools. Basic science studies using molecular imaging probes can help to identify and characterize disease-specific targets for oncologic drug therapy. Imaging end points, based on these disease-specific biomarkers, hold great promise to better define, stratify, and enrich study groups and to provide direct biological measures of response. Imaging-based biomarkers also have promise for speeding drug evaluation by supplementing or replacing preclinical and clinical pharmacokinetic and pharmacodynamic evaluations, including target interaction and modulation. Such analyses may be particularly valuable in early comparative studies among candidates designed to interact with the same molecular target. Finally, as response biomarkers, imaging end points that characterize tumor vitality, growth, or apoptosis can also serve as early surrogates of therapy success. This article outlines the scientific basis of oncology imaging probes and presents examples of probes that could facilitate progress. The current regulatory opportunities for new and existing probe development and testing are also reviewed, with a focus on recent Food and Drug Administration guidance to facilitate early clinical development of promising probes.

Value of Imaging-Based Biomarkers in Drug Development

In the last 10 years, novel treatments have been developed that prolong survival, induce remission, and provide better quality of life for cancer patients. Among the successes are the molecularly targeted cancer treatment drugs, notably the anti-HER-2/*neu* antibody trastuzumab for ErbB2-expressing breast cancers (1) and the kinase inhibitor imatinib for chronic myelogenous leukemia and gastrointestinal stromal tumors (2). In addition, molecularly targeted drugs have shown efficacy in lung cancer [e.g., the epidermal growth factor receptor (EGFR) inhibitor erlotinib; ref. 3], multiple myeloma (e.g., the proteasome inhibitor bortezomib; ref. 4), advanced colorectal cancer (e.g., the EGFR antibody cetuximab; refs. 5, 6), and other breast cancer settings (e.g., the aromatase inhibitor letrozole for hormone receptor–unknown or hormone receptor–positive locally advanced or metastatic breast cancer in postmenopausal women; ref. 7). Despite their efficacy in certain settings, molecularly targeted drugs are resource-intensive to develop, with the considerable expenditures, protracted time, and numerous patients required during development resulting in high costs of the approved therapy (8). Moreover, molecular targets have been identified and characterized in relatively few oncology patients; improved phenotypic characterization of the underlying molecular lesions would expand the overall effect of targeted agents in oncology.

Many other molecularly targeted agents, despite robust scientific rationale and promising preclinical and preliminary clinical results, have failed to show efficacy in definitive clinical trials (9). As an example, monotherapy with the EGFR inhibitor gefitinib did not improve survival compared with best supportive care in a recent Phase 3 trial in lung cancer patients. A small (10%) but encouraging response rate in refractory non–small cell lung cancer had supported its accelerated approval under Subpart H, with some patients experiencing striking and durable

Authors' Affiliations: [1]Cancer Imaging Program, Division of Cancer Treatment and Diagnosis, National Cancer Institute, NIH; [2]Molecular Tracer, LLC, Bethesda, Maryland; [3]Division of Nuclear Medicine, Department of Radiology, University of Washington, Seattle, Washington; [4]Memorial Sloan-Kettering Cancer Center, New York, New York; [5]Center for Molecular Imaging Research, Massachusetts General Hospital, Harvard Medical School, Charlestown, Massachusetts; [6]CCS Associates, Mountain View, California; [7]Baylor Charles A. Sammons Cancer Center, Dallas, Texas; [8]Lombardi Comprehensive Cancer Center, Georgetown University, Washington, District of Columbia; and [9]Office of Drug Evaluation, Division of Medical Imaging and Radiopharmaceutical Drug Products, and [10]Office of the Commissioner, Food and Drug Administration, Rockville, Maryland
Received 6/15/05; revised 8/11/05; accepted 9/1/05.
The costs of publication of this article were defrayed in part by the payment of page charges. This article must therefore be hereby marked *advertisement* in accordance with 18 U.S.C. Section 1734 solely to indicate this fact.
Requests for reprints: Gary J. Kelloff, Cancer Imaging Program, Division of Cancer Treatment and Diagnosis, National Cancer Institute, NIH, EPN 6130 Executive Boulevard, Suite 6058, Bethesda, MD 20892. Phone: 301-594-0423; Fax: 301-480-3507; E-mail: kelloffg@mail.nih.gov.
©2005 American Association for Cancer Research.
doi:10.1158/1078-0432.CCR-05-1302

Downloaded from clincancerres.aacrjournals.org on April 5, 2013. © 2005 American Association for Cancer Research.

responses. Emerging data suggest that certain EGFR mutations are more frequent in the patients responding to gefitinib (and other EGFR inhibitors), particularly nonsmokers, women, and those with adenocarcinoma histology or of Asian ethnicity (10–13). However, neither the phosphorylation status nor the expression of EGFR is predictive of response, and EGFR polymorphisms do not seem to correlate with relevant EGFR mutations (14). Thus, selection of non–small cell lung cancer patients likely to respond to EGFR inhibitors remains problematic.

Together, these difficulties highlight the need for faster, more efficient, and more cost-effective development of cancer therapeutics and for better definition of patients likely to benefit from treatment. As addressed by the recent Food and Drug Administration (FDA) Critical Path Initiative, collaborative interactions among such scientific knowledge areas as bioinformatics, genomics, materials science, and imaging technologies are needed to design and implement better drug development tools.[11] Important among these tools are molecular imaging probes that image specific molecular pathways *in vivo*, enabling visualization of phenotypic expression of key targets in the cancer disease processes. Unlike anatomic imaging, oncologic molecular imaging probes display biochemical and physiologic abnormalities underlying the cancer rather than the structural consequences of these abnormalities. Imaging-based biomarkers have many potential uses in all phases of the drug development process, from target discovery and validation to pivotal clinical trials for drug registration (see Fig. 1; see also ref. 15). First, as disease biomarkers, imaging end points can be employed to define, stratify, and enrich study groups. One such approach is to apply imaging-based probes in molecular target identification, characterization, and quantification to identify appropriate patient populations in which to test targeted agents. Second, clinical imaging studies of the labeled drug (e.g., in microdosing protocols; ref. 16) have potential to facilitate early clinical pharmacokinetic/pharmacodynamic assessments, including target interaction and modulation, particularly in patients where traditionally there are no direct measures of pharmacokinetics/pharmacodynamics throughout the tissues of the body and at the target. These approaches could be used in early studies comparing lead candidates designed to interact with the same target. A third area where imaging-based biomarkers have promise for speeding drug evaluation is by replacing or supplementing time- and labor-intensive dissection and histologic analyses in both preclinical and clinical testing. These noninvasive approaches may enable longitudinal preclinical studies with greater relevance to future clinical study designs. Finally, as biomarkers of tumor response, imaging end points (apoptosis, proliferation, angiogenesis, etc.) can also serve as early surrogates of therapy success.

Challenges to the development and implementation of molecular probe imaging modalities in drug development include the lack of validation and standardization of new as well as established imaging probes. In addition, imaging-based probes exist for only a few molecular targets or pathways, and substantial development work is often required. The regulatory development pathway for imaging agents, such as those developed as companions to new drug products, has often been proven challenging. The current regulatory approach has been the subject of much discussion and interest (17). Recent draft FDA guidance has addressed the hurdles to clinical testing in the exploratory setting, particularly to facilitate initial proof-of-principle testing.[12] Improved cooperation among imaging-based biomarkers and drug development efforts is warranted as has been addressed by a recent National Cancer Institute-FDA collaborative initiative.[13] In addition, imaging-based biomarker development could greatly benefit from recent advances in proteomic, genomic, and metabolic science that have led to the identification and characterization of key molecular targets in oncology.

This article outlines the scientific basis of oncology imaging probes and delineates areas where application of noninvasive or minimally invasive molecular imaging techniques could facilitate progress. Example probes are highlighted and settings in which imaging can meet clearly defined needs are discussed. These opportunities include enhancement of clinical risk stratification due to improved diagnostic capabilities, optimization of disease therapy based on molecular target characterization, and improved efficacy assessments. The current regulatory landscape for new probe development is also reviewed, with a focus on recent FDA guidance to facilitate early clinical development of promising probes. Specifically, the topics covered include the following:

- basic scientific themes for oncologic imaging probes, including scientific issues and challenges for imaging key molecular targets in cancer;
- imaging probes measuring fundamental properties of neoplasia (proliferation, apoptosis, angiogenesis, and hypoxia);
- example clinical applications of small-molecule, peptide, and antibody imaging probes;
- opportunities to develop new probes and to apply them in early drug development under the current regulations [i.e., the exploratory investigational new drug (IND) and the radioactive drug research committee (RDRC)]; and
- a summary of molecular imaging probe development and recommendations to further progress in this area.

Basic Scientific Themes for Cancer Imaging Probes

Prominent examples of targets for drug development include specific kinases, cellular receptors, and signaling molecules (ErbB/HER receptor tyrosine kinases, BCR-ABL, platelet-derived growth factor receptor, vascular endothelial growth factor (VEGF) receptor, Ras, phosphatidylinositol 3-kinase, etc.). Probes to image such targets have included small molecules, peptides, and antibodies labeled with radionuclides (e.g., ^{11}C, ^{18}F, ^{99m}Tc, and ^{123}I), fluorochromes, or magnetic ligands (see Table 1). Many of the clinically available molecular imaging probes can be visualized with nuclear imaging techniques, such as single photon emission computed tomography (CT) or positron emission tomography (PET). These methods afford high intrinsic sensitivity and unlimited depth penetration but are limited by low resolution (5 mm in humans); combined PET/CT

[11] The Critical Path Initiative. http://www.fda.gov/oc/initiatives/criticalpath/. FDA. Accessed March 8, 2005.

[12] Guidance for industry, investigators, and reviewers: exploratory IND studies. http://www.fda.gov/cder/guidance/6384dft.htm. FDA. Accessed April 29, 2005.

[13] Cancer Bulletin. http://www.nci.nih.gov/ncicancerbulletin/NCI_Cancer_Bulletin_021505/page9. National Cancer Institute. Accessed March 8, 2005.

Downloaded from clincancerres.aacrjournals.org on April 5, 2013. © 2005 American Association for Cancer Research.

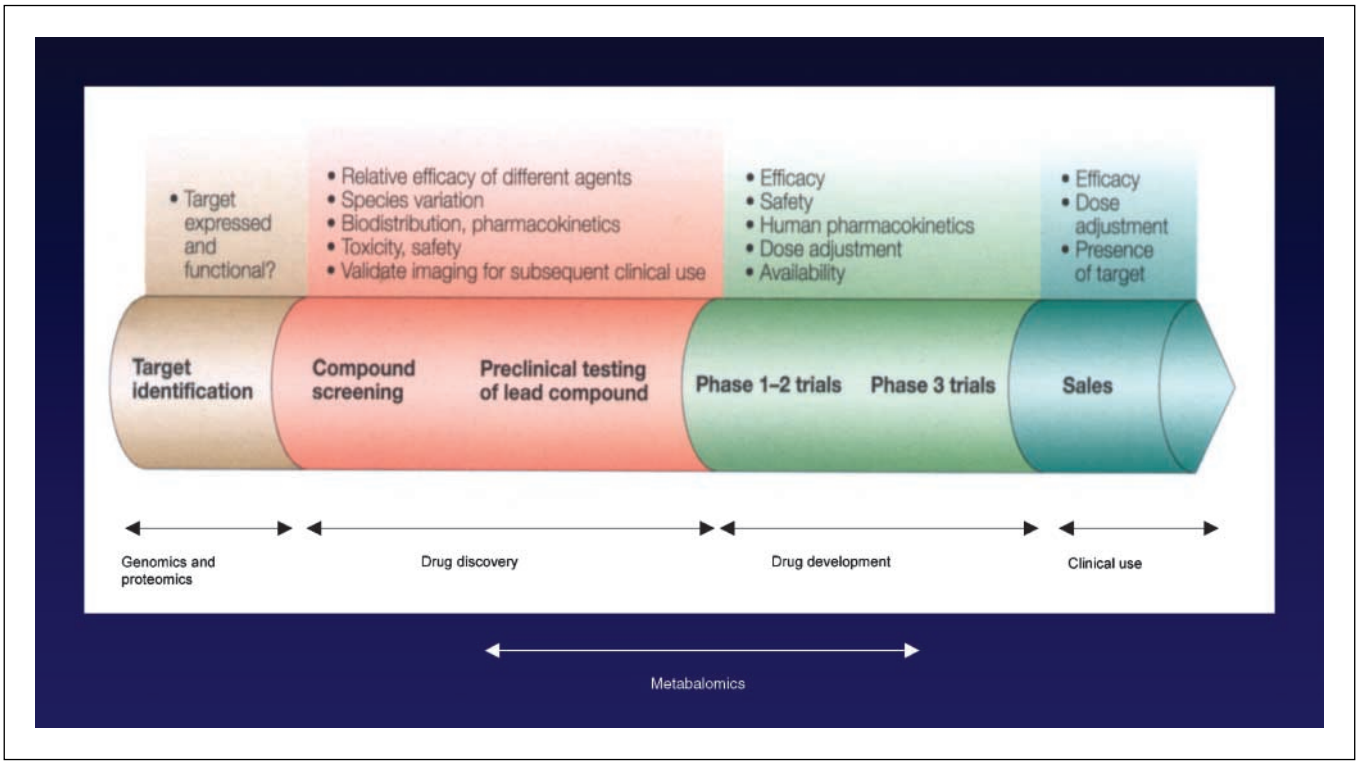

Fig. 1. Applications of imaging during drug discovery and development. Imaging-based biomarkers have many uses in all phases of the drug development process. They can aid in target discovery and validation and characterize drug-target interaction and modulation. Imaging end points can minimize time-intensive histologic analyses in both preclinical and clinical testing. As disease biomarkers, imaging end points can help define, stratify, and enrich clinical study groups. In addition to facilitating early clinical pharmacokinetic/pharmacodynamic assessments, imaging-based biomarkers can also serve as early surrogates of therapy success. [Reprinted with permission from Nature Reviews Drug Discovery (15)].

can enable more precise anatomic localization. Molecularly targeted probes for magnetic resonance imaging (MRI) include small-molecule/peptide/antibody-conjugated nanoparticles and other paramagnetic and superparamagnetic-based probes. Such probes permit simultaneous molecular and anatomic MRI whose resolution is much lower than the <1 mm seen with conventional, noncontrast anatomic MRI. The physical/chemical properties of the contrast agent (or molecularly targeted probe) and the S/N of the particular source of the signal also determine the resolution. Optical (e.g., near-IR fluorescence) imaging is a sensitive technique, although sensitivity decreases with depth due to attenuation. Resolution ranges from <1 mm to >1 cm depending on the depth of the source of the signal and the distance from the imaging device. Optical probes to several key oncologic targets (HER-2/*neu*, cathepsins, matrix metalloproteinases, etc.) are under development (18). Ultrasound is another high-resolution technique that has been applied to molecular imaging, but large-sized imaging particles are required (e.g., using microbubbles, liposomes, or perfluorocarbon emulsions as scaffolds; refs. 19, 20).

Despite their promise for characterizing targets and the functional consequences of drug-target interactions, the development of molecular imaging probes has faced several significant hurdles. For example, the targets are expected to have low (nanomolar to micromolar) concentrations; thus, adequate intracellular delivery and acceptable signal-to-noise amplification are necessary. Further, the molecular imaging probe should have a mass in tissues in the range of one-tenth to one-hundredth of the target(s) concentration so as not to exert mass or pharmacologic effects. In addition, molecular imaging probes have potential for nonspecific binding. Peptide and antibody receptor ligands afford greater specificity and binding affinity and are internalized within the cell on receptor binding, thereby taking advantage of inherent mechanisms for concentrating the molecule of interest. However, the peptides are rapidly cleared and degraded, and the larger peptides and antibodies can cause immunogenic reactions. Washout is another important consideration for all types of imaging probes; it must be sufficiently slow to allow accumulation of the probe at target sites but rapid enough to provide adequate target-to-background contrast. Practically, imaging probe development often occurs late in the drug development process, and the potential advantages afforded by the probe are not fully realized. In addition, the probe is often not subject to rigorous pharmacokinetic characterization and radiolabeling, and other types of labeling can change the binding properties of the small-molecule probes. The goal of labeling is to minimize this, avoiding a result of unfavorable kinetics that can limit the applicability of data from studies characterizing the drug. For example, metabolism of a radiolabeled probe can lead to uptake, distribution, and incorporation of products containing the radionuclide; thus, pharmacokinetic characterization can be essential to developing and validating kinetic models that accurately reflect the target.

Approaches being explored to address these hurdles include employing small peptides and antibody fragments that have limited antigenicity. Developments in peptide chemistry have improved targeting and facilitated synthesis, radiolabeling,

Downloaded from clincancerres.aacrjournals.org on April 5, 2013. © 2005 American Association for Cancer Research.

and linkage to chelators of small peptides or peptide fragments. Likewise, small-molecule probe discovery has been facilitated by novel chemical synthesis techniques, such as *in vitro* click chemistry. This approach employs the intended biological target (e.g., an enzyme) in the chemical assembly of inhibitors from complementary building block reagents (21, 22). Strategies, such as high-throughput screening, phage display, and nanotechnology, are also being applied in imaging probe development. Progress has been achieved in developing lower thresholds of detection, multivalency to improve target affinity, and cellular internalization and biological trapping of imaging ligands. As an example, small-molecule probes that are trapped on activation at the active site of the enzyme have been applied to image targets of the many drugs that bind to the ATP-binding pocket of kinases. Practical limitations include competitive binding of the probe, which is present in low concentrations, by high ATP levels. Such was found to be the case with ML01, a ^{18}F-labeled reversible inhibitor of EGFR (23). ML03, a ^{11}C-labeled irreversible EGFR inhibitor, was not subject to washout by ATP due to covalent binding of the probe at the tyrosine kinase domain of the receptor; however, nonspecific chemical reactivity limited the bioavailability and tumor accumulation of the probe (24). A newer generation of irreversible EGFR inhibitor probes has greater stability and thus improved potential for imaging EGFR (25). A separate issue to consider is the promiscuity of such inhibitors for other kinases as was addressed recently by determining the *in vitro* binding affinity of 20 inhibitors using a panel of 119 related protein kinases (26). The study identified a wide range of specificity that correlated with neither the chemical structure nor the intended drug target.

Table 1. Imaging probes used to visualize molecular targets and processes in cancer

Molecular target/process	Imaging probes (phase of development)
Small-molecule probes	
Proliferation	2-[^{11}C]Thymidine, FLT, 1-(2′-deoxy-2′-fluoro-β-D-arabinofuranosyl) thymine, 2′-deoxy-2′-fluoro-5-fluoro-1-β-D-arabinofuranosyluracil, [^{124}I]iododeoxyuridine (clinical testing)
Apoptosis	[^{99m}Tc]Annexin V, [^{18}F]Annexin V (clinical testing)
Hypoxia	[^{18}F]misonidazole, 2-(2-nitro-1H-imidazol-1-yl)-*N*-(2,2,3,3,3-pentafluoropropyl) acetamide, fluoroerythronitroimidazole, fluoroetanidazole, diacetyl-bis(*N*^{4}-methylthiosemicarbazone) copper (II), ^{124}I-labeled iodo-azomycin-galactoside, fluoroazomycinarabinofuranoside (clinical testing)
Pharmacokinetics	5-Fluorouracil, *N*-[2-(dimethylamino)ethyl]acridine-4-carboxamide,1, 3-bis(chloroethyl)-1-nitrosourea, [^{11}C]temozolomide, [^{13}N]cisplatin (FDA approved)
Multidrug resistance	[^{99m}Tc]sestamibi, [^{11}C]verapamil, [^{11}C]daunorubicin, [^{11}C]colchicine, [^{99m}Tc]methoxyisobutylisonitrile (FDA approved)
Breast cancer (ER)	FES (clinical testing)
Prostate cancer (androgen receptor)	FDHT (clinical testing)
Peptide probes	
Somatostatin/somatostatin receptor	[^{90}Y]1,4,7,10-tetraazacyclododecane-1,4,7,10-tetraacetic acid-Tyr^3-octreotide, [^{111}In]diethylenetriamine pentaacetic acid-D-Phe(1)-octreotide, [^{90}Y]1,4,7,10-tetraazacyclododecane-1,4,7,10-tetraacetic acid-lanreotide/vapreotide (FDA approved)
Vasoactive intestinal peptide/vasoactive intestinal peptide receptor-1	[^{123}I]Vasoactive intestinal peptide, [^{99m}Tc]TP3654 (clinical testing)
Bombesin, gastrin-releasing peptide/gastrin-releasing peptide receptor	[^{99m}Tc]Bombesin (clinical testing)
Cholecystokinin, gastrin/cholecystokinin receptor	[^{111}In]diethylenetriamine pentaacetic acid-minigastrin (clinical testing)
Angiogenesis	[^{18}F]Arg-Gly-Asp peptide targeted to $\alpha_V\beta_3$ integrin (preclinical testing)
Cathepsin proteases	Prosense (VM102) (preclinical testing)
Antibody probes	
Angiogenesis	Paramagnetic nanoparticles using antibodies to integrin $\alpha_V\beta_3$, the integrin $\alpha_V\beta_3$ ligand, vascular cell adhesion molecule 1, E-selectin (preclinical testing)
CEA	Arcitumomab (CEAscan), Satumomab (FDA approved)
Prostate-specific membrane antigen	Capromab pendetide (ProstaScint) (FDA approved)
CD20	^{131}I-labeled tositumomab (Bexxar), ^{90}Y-labeled ibritumomab tiuxetan (Zevalin) (FDA approved)
CD22	Bectumomab (clinical testing)

Downloaded from clincancerres.aacrjournals.org on April 5, 2013. © 2005 American Association for Cancer Research.

Together, these findings highlight the difficulties in imaging tyrosine kinases and other key molecular targets. However, there have been several significant successes. For example, several chemotherapeutic drugs have been labeled to assess drug pharmacokinetics as well as multidrug resistance (see Table 1). In general, these examples involve tracer doses of nontargeted drugs. A comparable approach employing radiolabeled analogues of molecularly targeted therapies also has promise for elucidating not only pharmacokinetic properties but also the specificity of the drug for the purported molecular target. Examples include a recent *in vitro* study of the inhibitory properties of biotinylated, [^{125}I]iodophenylated, and fluorescent analogues of the phosphatidylinositol 3-kinase inhibitor wortmannin (27). Peptide and antibody ligands linked to radionuclides and cytotoxins have been successful in cancer therapy (e.g., in treatment of hematologic and neuroendocrine tumors), and the radiolabeled peptide and antibody probes have been applied in oncologic imaging (see Table 1). Primarily, these agents have comprised antibodies and peptides that bind with high affinity to key receptors (e.g., somatostatin, bombesin, gastrin-releasing peptide, vasoactive intestinal peptide, and cholecystokinin receptors) or antigens [carcinoembryonic antigen (CEA), prostate-specific membrane antigen, and CD20]. Another promising area in which considerable progress has been made in target selection and signal amplification is for probes that image proteases. Protease cleavage activates the probe, resulting in high target-to-background signal ratios. Several proteases are up-regulated in cancer, including cathepsins, matrix metalloproteinases, urokinase-type plasminogen activator, etc. (28–30). These proteases play key roles in disease progression related to invasion, metastasis formation, high growth rates, and microenvironment host response and may represent key targets for imaging to detect cancers, measure their aggressiveness, and report on therapeutic efficacy of protease inhibitors. Optical protease imaging agents were first synthesized in the late 1990s, with magnetic resonance agents appearing more recently (31). The most efficient optical preparations have a 10- to 1,000-fold signal amplification on enzyme activation in preclinical *in vivo* studies.

A further consideration in molecular imaging is that up-regulation of some key oncologic molecules, such as EGFR, may be minimal or not highly correlated with outcome, limiting the value of measuring overexpression. Indeed, as shown in Fig. 2, other mechanisms, such as mutation and amplification, contribute more prominently to the anomalies seen in cancer, are more predictive of outcome, and are important targets for current and future imaging probe development (32). Another possibility is to image downstream molecules and events that may better reflect drug activity. Increasingly, molecular imaging probes are being developed to target proliferation, apoptosis, angiogenesis, hypoxia, and other cellular processes that are essential to carcinogenesis (Table 1). These in turn reflect tumor cell turnover, physiology, vitality, and blood supply. Such probes can be used in combination with those that enhance imaging of key molecular targets (e.g., proteases and receptor tyrosine kinases) that are prominently up-regulated in carcinogenesis. This dual-probe methodology would examine both molecular target modulation and downstream effect (see Fig. 3). For example, a decrease in phosphorylated extracellular signal-regulated kinase will occur when EGFR tyrosine kinase is inhibited and may in fact be a better indicator of inhibitor activity. Moreover, imaging the downstream cellular consequence of inhibition of phosphorylated extracellular signal-regulated kinase (e.g., increased apoptosis and reduced proliferation) may provide additional, complementary information about drug activity. This approach could also be used to improve selection of patients for EGFR inhibitor therapy and may prove more successful than imaging the actual drug target.

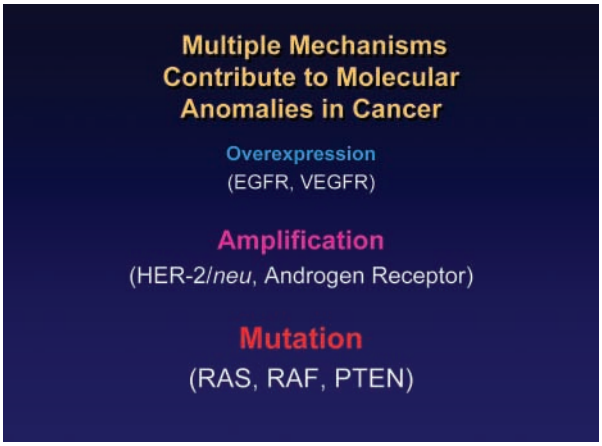

Fig. 2. Multiple mechanisms contribute to molecular anomalies in cancer. Mutations of oncogenes, suppressor genes, and modifier genes play a prominent role in carcinogenesis, and these lesions are most predictive of cancer development and progression. Another contributing mechanism is increased copy number of key genes, amplification, for which there are compelling examples (e.g., HER-2 amplification in breast cancer). Overexpression of key genes (leading to increased mRNA and protein) can arise via a variety of mechanisms, including compensatory means, and is least predictive of the development and progression of cancers. VEGFR, VEGF receptor.

Imaging Fundamental Properties of Neoplasia

This section describes the role of proliferation, apoptosis, angiogenesis, and hypoxia in cancer and the strategies to image these processes in oncology. Primarily, these include applying small-molecule PET probes. In the discussion, emphasis is given to the molecular basis of the probe, the history of its development, and its current applications. Perceived needs for future molecular imaging probe development to improve imaging of neoplastic processes are also addressed.

Proliferation imaging. The nucleoside thymidine can be incorporated into DNA by either the salvage pathway or the *de novo* pathway of DNA synthesis. The salvage pathway directly reflects proliferative activity and entails uptake, sequential phosphorylation, and ultimately DNA incorporation of exogenous thymidine. For >40 years, [^{3}H]thymidine incorporation has been the gold standard for assessing proliferation *in vitro*. Thymidine labeled with positron-emitting nuclides can enable *in vivo* imaging using PET. Like the tritiated derivative, thymidine labeled with ^{11}C in the pyrimidine ring provides the authentic substrate for the salvage pathway transporters, thymidine kinase, and DNA polymerase and is incorporated into DNA. However, the ^{11}C derivatives are also substrates for the catabolic pathway, yielding ^{11}C-CO_2 and other labeled derivatives (33). Validated kinetic models of [^{11}C]thymidine that account for this metabolism have been used to characterize

Downloaded from clincancerres.aacrjournals.org on April 5, 2013. © 2005 American Association for Cancer Research.

human tumors, including response to chemotherapy directed at the *de novo* DNA synthesis pathway (34). [^{124}I]Iododeoxyuridine has also been used to image proliferation (35) and response to therapy (36), but the approach is limited by the long half-life of the isotope, radiation dose, and hydrolysis of the iodine label.

The deoxyribose group of thymidine can also be labeled with ^{18}F at either 2′-arabino position or 3′-deoxy position. The former approach provides 1-(2′-deoxy-2′-fluoro-β-D-arabinofuranosyl) thymine or 2′-deoxy-2′-fluoro-5-fluoro-1-β-D-arabinofuranosyluracil (37, 38), whereas the latter yields 3′-deoxy-3′-fluorothymidine (FLT; ref. 39). The resulting fluorinated derivatives have practical advantages, including the longer half-life of ^{18}F versus ^{11}C (110 versus 20 minutes, respectively). However, these derivatives interact differently with nucleoside transporters and are poorer substrates than thymidine for thymidine kinase. In addition, 1-(2′-deoxy-2′-fluoro-β-D-arabinofuranosyl) thymine reacts preferentially with the mitochondrial rather than the cytosolic thymidine kinase isoform, which lacks specificity for the S phase of the cell cycle. Although FLT is not degraded by thymidine phosphorylase (40), it is glucuronidated. FLT is trapped intracellularly in a manner analogous to [^{18}F]fluorodeoxyglucose (FDG) because, following initial phosphorylation by thymidine kinase, the resulting monophosphate cannot be incorporated into DNA due to lack of a hydroxyl group. In general, FLT provides complementary information to FDG based on differences in regional distribution (39, 41). FLT uptake [expressed as the maximum standard uptake value (SUV)] at 60 minutes is roughly correlated with Ki-67 index, an immunohistochemical indication of proliferation (42). Although not likely to replace FDG for tumor detection and staging, FLT offers improved sensitivity or specificity in certain clinical situations (e.g., for distinguishing radionecrosis from recurrent brain tumor, for detecting indolent lymphomas, or for discriminating inflammation from tumor). FLT also has great potential utility in following response to therapy. A responding tumor cell may continue to metabolize FDG to maintain ion gradients or to provide energy for the P-glycoprotein (P-gp) pump function or protein biosynthesis; however, it will not synthesize new DNA and will not accumulate FLT. A decrease in DNA synthesis is likely following either cytostatic or cytotoxic therapy, highlighting the general utility of FLT PET for detecting response. Early clinical studies to quantify response will benefit from using rigorously quantitative methods to distinguish thymidine delivery and transport from thymidine kinase enzyme activity (43, 44). Comparative studies with SUV should lead to efficient protocols to assess proliferation in oncologic drug development.

Apoptosis imaging. Programmed cell death is an essential component of normal human growth and development, immunoregulation, and homeostasis. Cancer is as much a failure of apoptosis as it is a result of unchecked proliferation (45). Apoptosis also likely plays a significant role in cancer response to therapy. Many radiation and chemotherapy regimens kill cells by inducing apoptosis, and the development of resistance to apoptosis commonly limits response to cancer treatment (46). For this reason, a probe to noninvasively measure apoptotic cell death could prove useful for assessing the clinical response to chemotherapy.

When tumor cells detect DNA damage beyond the repair capability of the cell, programmed cell death pathways are triggered. Many of these are p53 dependent; the *p53* gene is mutated in the majority of human cancers (47). Apoptotic cell death can be initiated through an extrinsic pathway involving activation of cell surface death receptors or by an intrinsic pathway via the mitochondria (48). Both pathways lead to activation of effector caspases that trigger a proteolytic cascade resulting in fragmentation of intracellular components. One of the earliest effects of caspase activation is the disruption of the translocase system that normally maintains phosphatidylserine on the interior of the cell membrane. Together with up-regulation of a scramblase activity that also occurs on caspase activation, this results in the redistribution of phosphatidylserine to the outer membrane leaflet, where it serves as a signal to phagocytic cells to engulf and digest the membrane-enclosed apoptotic cells (49).

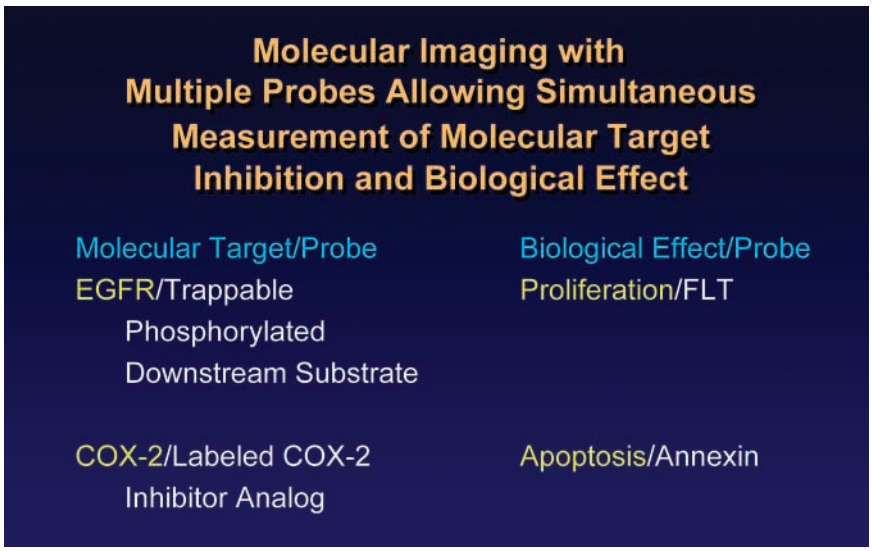

Fig. 3. Molecular imaging with multiple probes allowing simultaneous measurement of molecular target inhibition and biological effect. Imaging probes have been developed to reflect proliferation, apoptosis, angiogenesis, hypoxia, and other cellular processes that are essential to carcinogenesis (see Table 1). These fundamental biological properties are expected to be modulated in varying degrees by molecularly targeted therapies. Such probes therefore can be used in combination with probes that image drug-target interaction and/or modification to give a more complete picture of drug activity. COX-2, cyclooxygenase-2.

Downloaded from clincancerres.aacrjournals.org on April 5, 2013. © 2005 American Association for Cancer Research.

Annexin V is a 36-kDa protein that binds with high affinity (K_d, ~10 nmol/L) to externalized phosphatidylserine. Annexin V staining has become a standard histopathologic measure of apoptosis. The ^{99m}Tc-labeled Annexin V imaging probe lacked specificity in early clinical testing (50, 51). In addition to concerns about probe formulation, a separate issue was the apparent lack of specificity of phosphatidylserine expression for apoptotic cells. Positron-emitting Annexin V probes (labeled with ^{124}I and ^{18}F) were developed to take advantage of the higher resolution and improved quantitation with PET (52, 53). In initial preclinical validation studies, [^{18}F]Annexin V correlated with the terminal deoxynucleotidyl transferase-mediated dUTP nick end labeling *in vitro* assay (54). Fluorophore and iron oxide Annexin V derivatives are also being explored (55–59).

Active research is ongoing to measure apoptosis using other molecular effectors or inhibitors, including members of the inhibitor of apoptosis family of proteins, which function by binding and suppressing caspases (60, 61). Certain cancers overexpress the various inhibitors of apoptosis proteins (e.g., survivin, X-linked inhibitor of apoptosis, and livin), and small-molecule suppressors are being tested in early *in vitro* and *in vivo* studies. Short peptides that can reverse the resulting caspase inhibition are also being explored. Other targets include the Fas-associated death domain–like interleukin-1β-converting enzyme inhibiting protein, which seems to be an important determinant of resistance to apoptosis induction. Following validation in animals and successful early clinical testing, apoptosis imaging probes could be applied in the evaluation of cancer therapies, particularly for lymphoma and leukemia (62, 63). They could be especially useful in helping sequence multiagent treatment strategies.

Angiogenesis imaging. Angiogenesis is a key oncologic process that is essential for tumor growth and for the initiation of metastasis (64). Imaging modalities for detecting angiogenesis include methods to assess blood volume and flow and to derive semiquantitative and quantitative kinetic hemodynamic variables. In addition, targeted probes can be used to visualize molecular effectors of angiogenesis, such as VEGF and $\alpha_V\beta_3$ integrin (65). One approach for steady-state imaging of blood flow is to use magnetic nanoparticles, which have a long-lived intravascular nature. Because the images cover large areas of the body, both primary malignancies and metastases could potentially be evaluated (66–69). In tumor xenograft models of varying degrees of angiogenesis, magnetic nanoparticles selectively enhanced the vascularity without significant leakage into tumor interstitium (68). The models were characterized by determining microvessel counts, VEGF production, and global tumor intravascular volume fraction using a validated ^{99m}Tc marker (70, 71). In these experimental tumor models, steady-state measures of vascular volume fraction with MRI provided a volumetric, *in vivo*, noninvasive assay of microvascular density. Experiments are ongoing to determine the *in vivo* sensitivity of this steady-state technique for investigating antiangiogenic therapies in animal models and humans.

Neovascular density can also be imaged by direct or indirect specific molecular targeting. One preferred target has been the integrin $\alpha_V\beta_3$. Although also expressed on endothelial cells, $\alpha_V\beta_3$ integrins are found on a wide range of tumor cells, including the MDA-MB-435 breast and B16B15b melanoma cells (72) as well as human lung carcinoma (73) and melanoma (74). This receptor is up-regulated in angiogenic endothelium and has been imaged using an Arg-Gly-Asp–containing peptide with high affinity for α_V integrins or using antibody-conjugated nanoparticles (72, 75–79). Using a nanoparticle comprising an antibody to the integrin $\alpha_V\beta_3$ ligand, micrometastases could be detected and characterized in a melanoma mouse model (80). The same ligand has been exploited in other MRI-targeted approaches either using antibodies conjugated to liposome nanoparticles sequestering gadolinium or other direct antibody conjugations to nanoparticles (81).[14] E-selectin offers another target that has been exploited by MRI using either paramagnetic (82, 83) or superparamagnetic nanoparticle approaches (84). Another exciting target that has recently been explored is vascular cell adhesion molecule 1.

Hypoxia imaging. In solid tumors, hypoxia may result from unregulated cellular growth, but it is also a common attribute of the tumor phenotype and may even be a factor in tumorigenesis. Hypoxia induces tissue changes that result in selection of cells with mutant p53 expression (85–89). Indeed, after DNA damage, hypoxic cells do not readily undergo apoptosis (90, 91). Hypoxia enhances expression of endothelial cytokines, such as VEGF, interleukin-1, tumor necrosis factor-α, and transforming growth factor-β, and a cellular O_2 sensing mechanism triggers production of hypoxia-inducible factor-1α (92). A subunit of the basic-helix-loop-helix transcription factor hypoxia-inducible factor-1 that is activated by redox-dependent stabilization, hypoxia-inducible factor-1α induction initiates a cascade of events culminating in angiogenesis. Tumor hypoxia and hypoxia-inducible factor-1α activation may also contribute to the metabolic switch to glycolysis that characterizes tumor cells (93). However, many cancer cells use glycolysis for energy production regardless of the availability of oxygen, suggesting that the two processes are independent (94).

Hypoxia is prevalent in nearly all tumors studied and predicts radiation response in sarcoma, glioma, and cancers of the uterine cervix, lung, and head and neck (for recent reviews, see refs. 95, 96). In addition to significant interpatient differences in the distribution of hypoxia, microscopic heterogeneity also occurs within a tumor (97). The level of oxygenation, even in well-perfused tissues, is extremely variable. In patients with head and neck cancer, oxygenation at one site correlated well with other sites (98). Hypoxia in tumors does not depend on tumor size, grade, and extent of necrosis or blood hemoglobin status and seems to be an independent predictor of outcome (96, 99, 100).

In addition to inducing radioresistance, hypoxia promotes resistance to several chemotherapeutic agents potentially through three mechanisms. Hypoxia impedes drugs from reaching the cells from blood vessels, slows proliferation, and promotes gene expression changes that enable cellular rescue from severe damage (101, 102). To address the clinical problem of tumor resistance associated with hypoxia, the focus for several decades has been to improve O_2 levels in the tumor environment or to use O_2-independent irradiation (neutrons), altered fractionation, or radiosensitizers. However, these techniques have been associated with problems of low availability or serious clinical toxicity. An alternative strategy is to selectively target hypoxic cells with hypoxia-activated prodrugs. The introduction of the relatively nontoxic, bioreductive, hypoxia-activated prodrug, tirapazamine, has rekindled interest in identifying

[14] X. Montet, personal communication.

Downloaded from clincancerres.aacrjournals.org on April 5, 2013. © 2005 American Association for Cancer Research.

patients with tumor hypoxia (100). A second way to exploit hypoxia is to employ therapies that take advantage of hypoxia-inducible factor-1α activation under hypoxic conditions (103).

PET imaging is an ideal modality for evaluating hypoxia. It images the entire tumor and is less operator-dependent than oxygen electrodes. Its safety profile and noninvasiveness make it useful in patient follow-up. The PET imaging agent fluoromisonidazole is a ^{18}F-labeled fluorinated derivative of misonidazole, an azomycin hypoxic cell sensitizer introduced two decades ago, which binds covalently to intracellular molecules at a rate inversely proportional to intracellular O_2 concentration. Its uptake in hypoxic cells is dependent on the reduction of the nitro group on an imidazole ring (96). Fluoromisonidazole is easily synthesized (104), has a long record of use in humans, involves only modest radiation exposure (105), and has undergone extensive clinical validation. Second-generation agents include 2-(2-nitro-1H-imidazol-1-yl)-*N*-(2,2,3,3,3-pentafluoropropyl) acetamide (106), fluoroerythronitroimidazole, a more hydrophilic variant of fluoromisonidazole, and fluoroetanidazole, which has binding characteristics similar to fluoromisonidazole but with decreased hepatic retention and fewer metabolites (107, 108). The nitroimidazole derivatives have similar blood clearance characteristics despite different partition coefficients. A ^{64}Cu-labeled acetyl derivative of pyruvaldehyde diacetyl-bis(N^4-methylthiosemicarbazone) copper (II) and ^{124}I-labeled iodo-azomycin-galactoside have the potential advantage of longer half-lives for clinical use (109–111).

Because hypoxia is associated with poor response to both radiation and chemotherapy, identifying hypoxia should have prognostic value. Recent advances in patient-specific radiation treatment planning, such as intensity-modulated radiotherapy, have enabled customization of radiation delivery based on physical conformity, but it can also incorporate variables, such as hypoxia, proliferation, and tumor burden to generate a biological profile of the tumor (112). In addition to its potential for defining the biological microenvironment of a tumor, hypoxia imaging also can help in selecting and directing the appropriate treatment, both radiation and chemotherapy (95). Hypoxia imaging during treatment might also enable advantageous treatment modifications.

Clinical Applications of Imaging Probes

The potential of the application of molecular imaging tools to enhance oncologic drug development and cancer patient management is discussed in five case studies. These example clinical settings include breast cancer, prostate cancer, multidrug resistance, neuroendocrine tumors, and lymphomas. Some of the imaging probes discussed in this section are approved and are used in routine clinical practice to direct cancer therapy (e.g., ^{111}In-labeled pentetreotide or capromab). As noted in Table 1, many of the others (e.g., ^{18}F-labeled estrogens or androgens) have been tested in investigational clinical studies but are not currently used to direct therapy. Examples of both classes of agents illustrate the realized and potential clinical utility of molecular imaging probes to direct cancer treatment.

Molecular imaging of estrogen receptor for breast cancer. Hormonal therapy of breast cancer is one of the earliest successes of targeted therapy, with the estrogen receptor (ER) as the therapeutic target (113). ER is expressed in most breast cancers; in most cancers expressing ER, interrupting estrogen-stimulated proliferation halts tumor growth and leads to tumor regression. Current hormonal therapies function by competing with estrogen metabolites for the receptor (tamoxifen), by inducing ER degradation (fulvestrant), or by lowering agonist concentration (aromatase inhibitors; ref. 114). The success of aromatase inhibitor therapy has increased the clinical utility of hormonal therapy in both primary and recurrent diseases. It has also spurred interest in novel hormonal agent development and in overcoming clinical hormone resistance. In parallel, there has been increased interest in characterizing ER expression and estrogen binding *in vivo* with PET to guide hormonal therapy in clinical trials and clinical practice.

Although no compound is currently in clinical use, several agents have been tested for PET ER imaging (115), and new compounds continue to be evaluated (116). The close analogue of estradiol, 16α-fluoroestradiol-17β (FES; ref. 117), has had the best results for imaging and quantifying the functional ER status of breast cancer by PET. The quantitative level of FES uptake in primary tumors correlates with the level of ER expression measured by *in vitro* radioligand-binding assay (118) and, in preliminary studies, by immunohistochemistry (119). FES PET provides sufficient image quality to visualize metastatic lesions with high sensitivity in patients with ER-positive tumors (120, 121).

As a quantitative, noninvasive measure of regional estradiol binding to ER, FES PET provides capability not possible by biopsy and *in vitro* assay. FES PET can provide specific characterization of sites identified by nonspecific methods, such as CT or FDG-PET. In a diagnostic sense, documentation of estradiol binding at sites suspicious for breast cancer recurrence or metastasis provides highly specific evidence of breast cancer (121). In assessing ER expression, FDG and FES PET are complementary. FDG identifies active sites of cancer and can be used to indicate where to interrogate the FES PET scan for tumor ER expression. This approach is especially important for identifying active areas of disease with low or absent ER expression but requires two different scanning days, because both are ^{18}F-labeled compounds. Image interpretation and analysis is facilitated by FDG/FES PET image coregistration. Combined PET/CT devices, which fuse functional and anatomic imaging, may also be helpful in this regard.

Perhaps most importantly, FES PET may provide a predictive assay, in analogy to *in vitro* assay of ER expression in biopsy material, for directing hormonal therapy in drug trials and in clinical practice. FES PET can assess ER expression at all sites of disease in patients with large primary breast cancers and/or metastatic lesions and overcome potential sampling error inherent to *in vitro* assays (122). As shown in Fig. 4, this could be especially valuable when evaluating recurrent disease. Dehdashti et al. (120) showed that, by FES/FDG-PET, ~15% of patients with metastatic disease from an ER-positive primary tumor have one or more ER-negative metastatic sites. This is consistent with recent studies based on biopsy (123). Low or absent ER expression predicts a very low likelihood of response to hormonal therapy (124). Mortimer et al. (125) showed that, for patients with locally advanced or metastatic breast cancer, low FES uptake (SUV < ~2) before primary tamoxifen therapy predicted nonresponse. In a recent study, Linden et al. (126) showed similar results for a heavily pretreated population with recurrent or metastatic breast cancer and found that only patients with at least modest pretherapy FES uptake (SUV > 1.8)

Downloaded from clincancerres.aacrjournals.org on April 5, 2013. © 2005 American Association for Cancer Research.

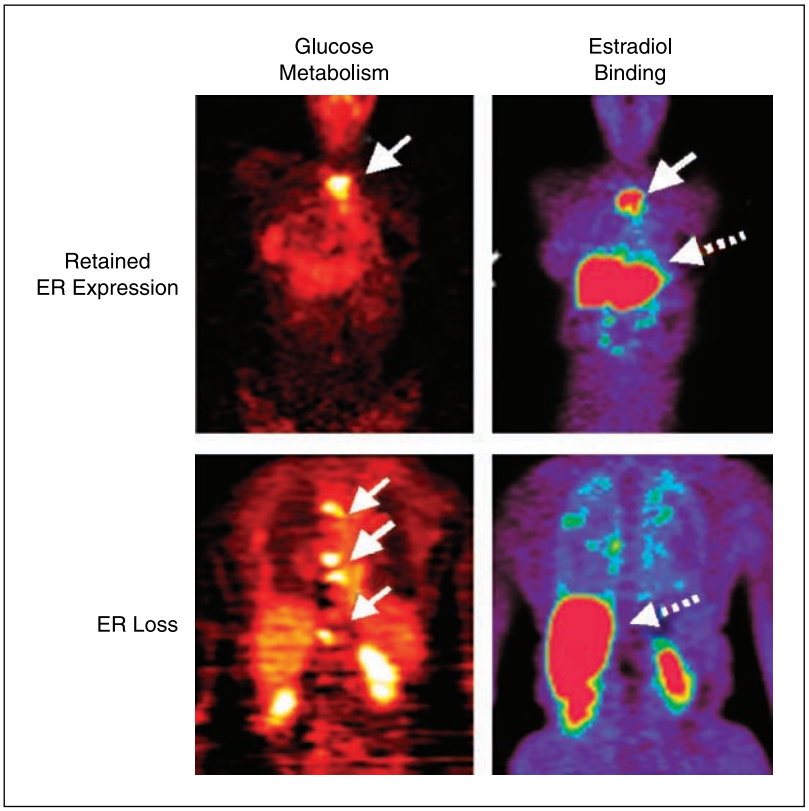

Fig. 4. Coronal images of glucose metabolism (*left*) and estradiol binding (*right*) obtained by FDG and FES PET, respectively, in two patients with recurrent breast cancer. Solid arrows, tumor sites; dashed arrows, the normal liver, the site of FES metabolism, in both FES images. Both patients had recurrent disease from ER-expressing primary breast cancers and were treated with hormonal therapy. Top, PET images of the patient show high-level estradiol binding in a sternal metastasis, indicating retained ER expression. This patient had an early and sustained response to letrozole. Bottom, the patient had multiple active bone metastasis on the FDG-PET scan but no estradiol binding, indicating a loss of functional ER. This patient failed hormonal therapy and had disease progression on multiple different hormonal regimens.

had an objective response to hormonal therapy, mostly aromatase inhibitors. In the Linden et al. study, a hypothetical treatment algorithm using FES PET to select patients for hormonal therapy would have increased the response rate from ~25% to ~50%, without inappropriately withholding therapy from patients destined to respond.

FES PET can also be used to measure the effect of hormonal therapy on the therapeutic target, the ER. McGuire et al. (127) showed near complete blockade of ER by tamoxifen, and subsequent studies by Mortimer et al. (125) and Dehdashti et al. (128) showed that a decline in FES uptake early after starting tamoxifen was predictive of response. Interestingly, prior hormonal therapy does not necessarily promote ER loss; in fact, patients resistant to tamoxifen because of previous treatment did not have lower average ER expression (119). This is consistent with hypotheses that tamoxifen resistance is associated with changes downstream of the estradiol binding to the receptor and with cross-talk with other growth pathways (129). The ability to measure the *in vivo* pharmacodynamics of hormonal agents at the level of the receptor makes FES PET a potentially very useful tool for drug development and early testing.

In summary, PET ER imaging using FES has been validated and tested in preliminary patient studies as a tool for measuring ER expression at all sites of disease and as a predictive assay for hormonal therapy. Formal validation in prospective clinical trials is required. Future applications as a tool for hormonal agent drug development and testing as well as for use in clinical practice to guide hormonal therapy seem quite promising and likely.

Molecular imaging of androgen receptor in prostate cancer. Blockade of androgen action by medical or surgical means is standard front-line therapy for patients with advanced prostate cancer. Most traditional approaches are focused on reducing the production or action of the native ligand, testosterone. Testosterone is converted in the prostate to dihydrotestosterone, which in turn binds to and activates the androgen receptor. The activated receptor regulates the transcription of a range of target genes. The clinical benefits of castration, as practiced traditionally, are focused on the ligand rather than on the receptor. Response is a function of the degree to which the tumor is dependent on androgens for growth and survival. It is not, however, a curative strategy; over time, virtually all tumors progress. In the clinical state model of prostate cancer progression, patients who have failed androgen ablative therapies are separated based on the measured testosterone concentrations in the blood as either noncastrate or castrate (130). Castration-resistant disease represents the lethal variant of prostate cancer, as the majority of patients eventually die of disease.

Much research has focused on the mechanisms of tumor progression despite castrate levels of testosterone. The androgen receptor seems to remain functional, and signaling is sufficient to support continued tumor growth and progression. The evidence includes increased prostate-specific antigen levels at the time of progression, the responses to second-line and third-line hormonal manipulations that further reduce the ligand by blocking adrenal androgen synthesis, the steroid hormone withdrawal responses, and the benefits of nilutamide and bicalutamide (agents that act exclusively by androgen receptor binding).

Recent research by several groups suggests several non-mutually exclusive mechanisms of continued androgen receptor signaling, including the following: mutations in the ligand-binding domain leading to promiscuous activation by a range of steroidal hormones and nonsteroidal antiandrogens; increased levels of wild-type receptors; increased intratumoral levels of adrenal androgens, which may be related in part to an

Downloaded from clincancerres.aacrjournals.org on April 5, 2013. © 2005 American Association for Cancer Research.

increase in adrenal androgen synthetic enzymes; and ligand-independent activation of the receptor by growth factors, such as receptor tyrosine kinases and cytokines. Although a detailed discussion of these mechanisms is beyond the scope of this article, they do provide a rationale for the development of therapies targeting the receptor directly and for the ability to visualize the receptor *in vivo*. The clinical development of such therapies (including selecting patients most likely to respond to a given treatment, determining a dose and schedule, etc.) would be enhanced significantly if it were possible to assess the presence and the level of receptor within a tumor and to measure changes in the receptor following treatment.

16-Fluoro-5-dihydrotestosterone (FDHT) was developed and characterized in the mid-1990s (131). This radiotracer binds with high affinity to androgen receptor and has been employed to study androgen receptor expression in animals and humans. This agent, as with FES, has been used only in experimental clinical trials. Initial clinical studies included a few patients with progressing, androgen-independent prostate cancer manifested by rising prostate-specific antigen values documented on three or more occasions, castrate (<50 ng/mL) levels of testosterone, and metastatic disease visible by conventional imaging (CT or MRI and/or bone scan). The characteristics of androgen receptor expression in prostate cancer metastases were compared with [^{99m}Tc]medronate bone scan and [^{18}F]FDG metabolism (132, 133). A secondary goal was to characterize biodistribution, metabolism, and radiation dosimetry (133). Of the 59 lesions found by conventional imaging methods, 57 (97%) were positive with FDG, with an average SUV of 5.2. Of these metabolically active lesions, 48 (80%) were FDHT positive, with an average SUV of 5.3. In two patients treated with testosterone, FDHT tumor uptake was reduced (Fig. 5). This small study suggests that FDHT is actively concentrated in metastatic tumor sites of patients with androgen-independent prostate cancer, that uptake can be blocked by circulating androgen, and that this radiotracer is likely to be a useful tool for helping to understand the role that the androgen receptor may play in prostate cancer progression. The study also found a rapid conversion of the radiotracer to inactive metabolites, with 80% of FDHT disappearing from the plasma within 10 minutes.

In a recent 20-patient study, Dehdashti et al. (134) also used FDHT-PET to assess the effectiveness of pharmacologic androgen blockade. Patients with one or more foci of FDHT uptake in the castrate state were studied after administration of the androgen antagonist flutamide. In all 12 patients who received flutamide (250 mg thrice daily) for 1 day, the SUV decreased from an average of 7 to 3, indicating that flutamide effectively blocked FDHT uptake in this patient group. This study shows the feasibility of FDHT imaging in patients with advanced prostate cancer and suggests that uptake is a receptor-mediated process. In addition, it was noted that positive FDHT-PET studies were associated with higher prostate-specific antigen levels.

In summary, FDHT-PET imaging is feasible in patients with advanced prostate cancer with testosterone levels that are in the castrate range. There is active uptake of FDHT in the majority of metastatic lesions that are detected by conventional imaging. These recent data suggest that FDHT will be a valuable tracer for studying the biology of prostate cancer metastasis and for determining the effectiveness of androgen receptor blockade in these patients.

Imaging multidrug resistance. Molecularly targeted imaging probes have a potential role in identifying acquired resistance to chemotherapy, which is important in managing the treatment of most cancer patients. Doxorubicin (Adriamycin), vincristine (Oncovin), etoposide (Vepesid), taxanes (Taxol, Taxotere), and other chemotherapy drugs are subject to drug resistance as a

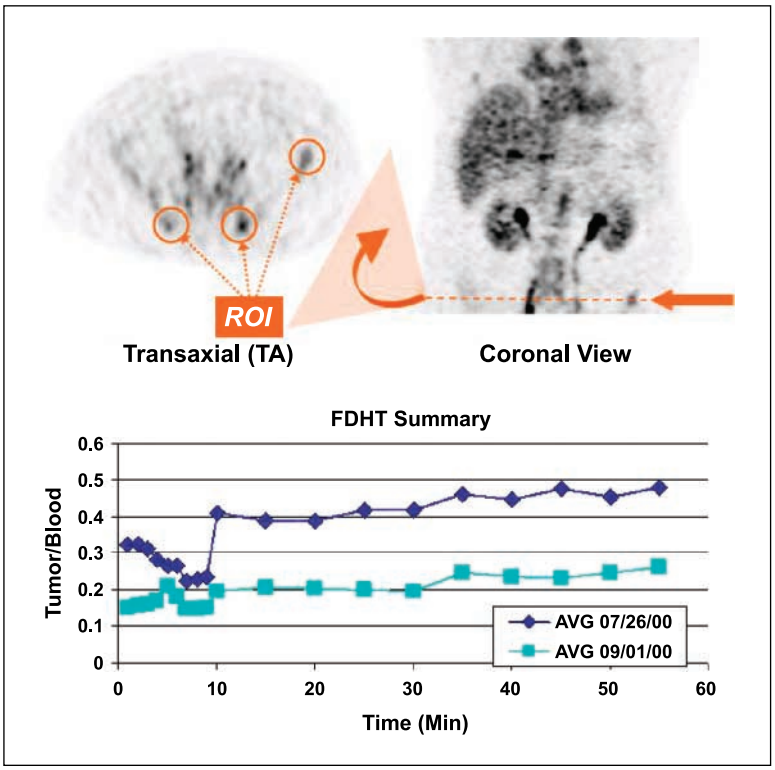

Fig. 5. Hormone-refractory prostate cancer patient who was imaged by FDHT before and after testosterone treatment. Top, pretreatment coronal and transaxial image displays containing three tumor sites in the pelvis (left iliac crest, left and right sacroiliac joints) on which regions of interest were drawn. Bottom, time activity curves before (*dark blue*; *top*) and after (*light blue*; *bottom*) treatment with testosterone. Y axis, average of all three lesion tumor/blood ratios for clarity, although all three tumors showed significant suppression of FDHT uptake after treatment.

Downloaded from clincancerres.aacrjournals.org on April 5, 2013. © 2005 American Association for Cancer Research.

result of increased expression of P-gp or related membrane transporter proteins (135–137). Imaging probes can quantify efflux of these drugs via the P-gp and other transporters.

One approach to imaging multidrug resistance in experimental studies measures the tumor efflux level of [^{11}C]verapamil, a well-characterized substrate for P-gp (138–141). In one study, the tumor clearance half-life of [^{11}C]verapamil was relatively fast (high P-gp; ref. 140), which could explain the inability of [^{11}C]verapamil coadministration to modulate resistance to chemotherapeutics, such as taxanes in solid tumors. In nonhuman primates, brain uptake increased ~2-fold when P-gp was inhibited by cyclosporine A (141). These results were confirmed in a clinical study, showing that [^{11}C]verapamil PET can be used to measure P-gp inhibition (142). Another effective imaging substrate for multidrug resistance that has been well studied in several human cancer settings involving chemotherapy resistance is [^{99m}Tc]sestamibi.

A standardized PET methodology for assessing the activity of the P-gp would provide important information about drug resistance in cancer patients at the time of diagnosis. It could be used to test the variability of this mechanism among patients and the extent to which P-gp resistance increases with exposure to chemotherapy. Institution of multidrug chemotherapy following early recognition of P-gp expression is called risk-adapted therapy, an extremely important concept for managing care of individual cancer patients that has increased survival in osteosarcoma patients (137).

Peptide probes in neuroendocrine tumor imaging. Oncologic peptide research has focused on identification of suitable targets (e.g., overexpressed peptide receptors) as well as the discovery and development of radiolabeled agents that can interact with these targets for therapeutic and imaging purposes. New targets include the gastrin-releasing peptide receptors in prostate and breast cancer and neuropeptide Y receptors in breast cancer. As noted above (see Fig. 2), deeper insight into receptor pathogenesis in cancer is needed, particularly with regard to the mechanisms of up-regulation in primary tumor as well as metastases, functional activity of receptors and receptor-ligand binding in tumors and peritumoral tissues, effect of receptor homodimerization and heterodimerization, and activity of endogenous peptide substrates. Several peptide receptor-binding compounds have been radiolabeled and are currently undergoing *in vitro* testing, *in vivo* validation, and clinical trials for radiotherapy or imaging; examples in clinical use are summarized in Table 1. Limitations of imaging specificity for these peptide probes include physiologic uptake in many inflammatory and granulomatous conditions (143). In addition, the signal intensity correlates better with receptor density than tumor size but is highly predictive of response to peptide analogue or radioligand therapy. A reduction in intensity during therapy could signal differentiation rather than response; combined FDG-PET scans can help discriminate these two processes.

One prominent successful group of peptide probes is the small (1.5 kDa) radiolabeled peptide analogues of somatostatin, the primary imaging agent for neuroendocrine tumors (144). Somatostatin receptors are expressed at high density in most neuroendocrine tumors as well as in pancreatic (insulinomas) and other cancers. Five receptor subtypes have been identified, which variously affect multiple cellular signaling cascades (including mitogen-activated protein kinase, phospholipase A_2, and cyclic AMP protein kinase A pathways). Tumors frequently express two or more subtypes, and homodimerization and heterodimerization can result in a range of functional characteristics. Based on the known mechanisms of action of somatostatin analogues, the receptors directly control proliferation and apoptosis as well as mediate indirect effects. The latter range from growth factor and hormone secretion to angiogenic and immunomodulatory effects. Radiolabeled somatostatin analogues include the approved agent diethylenetriamine pentaacetic acid-D-Phe(1)-pentetreotide (Octreoscan), widely used in clinical practice (see Table 1). Metal chelators (e.g., 1,4,7,10-tetraazacyclododecane-1,4,7,10-tetraacetic acid) have improved the stability of the radioconjugates, enabling incorporation of various radionuclides, such as ^{68}Ga for PET or ^{90}Y for radiotherapy.

Radiolabeled somatostatin analogues are well tolerated and have high affinity for the receptor. The most common somatostatin analogues (octreotide, lanreotide, and vapreotide) bind mainly with receptor subtypes 2 and 5. However, radiolabeled depreotide (Neotect) also has affinity for subtype 3 and can image tumors expressing these receptors, such as insulinomas. Most (85%) carcinoid neuroendocrine tumors, which have an 80% to 90% incidence of subtype 2A receptors, can be imaged with ^{111}In-labeled pentetreotide. Somatostatin receptor imaging can also identify and localize metastatic lesions and is thus useful in staging and treatment and surgical planning. In one study, ^{111}In-labeled pentetreotide altered patient management in 47% of 122 gastrinoma patients (145). Further, as also discussed below, imaging (e.g., using ^{86}Y-labeled somatostatin analogues; ref. 146) to define patient-specific dosimetry is being explored. In addition to their role in neuroendocrine tumors, which express a high density of somatostatin receptors, these imaging agents also have application in a wide range of tumors. These include meningiomas and medulloblastomas as well as cancers with low and heterogeneous receptor expression, such as small cell lung cancer, breast cancer, gastrointestinal cancers (including colorectal cancer), lymphoma, and renal cell carcinomas. Ongoing effort is focused on developing radiolabeled somatostatin analogues with enhanced resistance to proteases, specificity for certain somatostatin receptor subtypes or with broad specificity, or enhanced uptake.

Antibody probes: progress in clinical imaging. Radiolabeled antibodies take advantage of the natural biochemical specificity of the immune system to provide molecularly targeted agents for cancer imaging (147–150). In principle, because antibodies can be made against virtually any biomolecule, there is opportunity to develop radiotracers that target many physiologic and pathophysiologic processes of importance to cancer biology, diagnosis, and therapy. Early pioneering work in this field, which began in the 1950s, was reviewed by Pressman (151). Despite the long history of active research, development of radiolabeled antibodies as practical diagnostic and therapeutic radiotracers has been slow to mature. Impediments to progress include the following:

- Tissue antigen targeting is slow and variable compared with small imaging probes. Whole immunoglobulin (IgG) has a high molecular weight (160 kDa) and thus may take several days to equilibrate with tissue antigens outside the blood. In addition, the increased hydrostatic pressure in tumors arising from inadequate lymphatic function slows or impedes tumor penetration of radiolabeled antibodies (152).

Downloaded from clincancerres.aacrjournals.org on April 5, 2013. © 2005 American Association for Cancer Research.

- *In vivo* bioavailability for tumor target antigens is often compromised by cross-reactivity with normal tissue antigens. In some instances, tumor targeting may be improved by increasing the mass amount of the specific antibody (150, 153).
- Instability and *in vivo* metabolism of the radiotracer can interfere with tumor detection and result in normal tissue toxicity. When the radioantibody conjugate is metabolized, the radiolabel may distribute based on the characteristics of the metabolized conjugate fragments as well as on the characteristics of the radiolabel, confounding the imaging results. Further, toxicity may occur when the radioantibody conjugate is metabolized and the radiolabel is distributed to unintended organs [e.g., thyroid, stomach and kidney (radioiodine), or liver and kidney (most radiometals)].
- The production methods are biologically based and complex; quality control is challenging, and as such, regulatory approval may be prolonged. The hybridoma technique of Kohler and Milstein (154) was a major achievement, but advanced molecular imaging techniques have been necessary to produce optimized nonimmunogenic antibody reagents (155).

Several first-generation radiolabeled antibody products have received new drug application approval by the FDA as suitable for diagnosis or therapy of human tumors (see Table 1). Differentiation antigens that can serve as tumor burden markers have had the greatest success to date. For example, CEA was one of the earliest targets for detection and radiotherapy. Extensive work in the late 1970s and early 1980s used a variety of antibodies primarily labeled with iodine radionuclides (147, 156). Despite high rates of detection, the methods depended on γ-imaging and were considered too insensitive for routine use. The commercial product arcitumomab (CEAscan) is a ^{99m}Tc-labeled F(ab′) fragment that addresses several limitations of the radioiodine-labeled whole IgG products. First, compared with whole IgG, the ab′ fragment localizes much faster to tumor and is more rapidly cleared, thus providing greater tumor to normal tissue contrast. Secondly, F(ab′) fragments are significantly less immunogenic than whole IgG; thus, repeated imaging is possible even when the product is based on a murine antibody (157). Finally, the ^{99m}Tc label is more ideally suited for single photon emission CT imaging, which affords better contrast than conventional γ-imaging and is therefore superior for detecting tumors deep within the body. Several successful clinical trials have been reported with arcitumomab (158), including for detection of occult colorectal cancer when conventional imaging methods, such as CT, are negative (159). However, FDG-PET is preferentially used for detecting recurrent colorectal cancer due to its improved accuracy (160) and ease of implementation compared with the single photon emission CT arcitumomab technique. Arcitumomab is also effective in detecting medullary cancer of the thyroid (161). These tumors are difficult to diagnose and may be missed by FDG-PET if well differentiated, but FDG-PET and arcitumomab scans have not been directly compared in medullary thyroid cancer.

A second approved antibody probe is capromab pendetide (ProstaScint). An IgG1 murine monoclonal antibody (7E11-C5.3) conjugated to the linker-chelator, glycyl-tyrosyl-lysyl-diethylenetriamine pentaacetic acid, capromab pendetide reacts with an intracellular or internal epitope of prostate-specific membrane antigen. Prostate-specific membrane antigen is widely expressed in prostate and prostate cancer but not in other tissues. ^{111}In-labeled capromab pendetide is most useful in patients with high-risk, primary prostate cancer (Gleason ≥7 with prostate-specific antigen > 10 times the normal; refs. 162, 163) or suspected recurrent prostate cancer after prostatectomy. In a large clinical trial, the advantages derived primarily from detection of soft tissue and especially lymph node metastases (164). Nevertheless, the benefits of this technique remain controversial, as bone metastases are the primary cause of morbidity and mortality, and these lesions are more accurately detected by bone scanning. The imaging technique is difficult to perform, and fusion imaging of the capromab pendetide single photon emission CT with CT or MRI is a highly valuable adjunct (164). In addition, it has been reported that capromab pendetide lacks utility for predicting response to salvage radiation therapy (165).

Radiolabeled CD20-reactive antibodies have been used to treat non-Hodgkin's lymphoma. These include ^{131}I-labeled tositumomab (Bexxar), to which responses are seen in about two thirds of patients who have failed rituximab (Rituxan) and/or chemotherapy. Half are complete responses, and the response duration is ~1 year (166). The treatment regimen entails immediate prior administration of nonradioactive tositumomab together with a tracer amount of its radiolabeled counterpart. This dosimetric dose is used to assess the patient-specific pharmacokinetics at three time points using γ-imaging, from which the subsequent therapeutic dose is calculated. ^{131}I-labeled tositumomab is not approved for use in first-line therapy, but initial results in this setting are promising, with most patients in long-term complete remission (167). ^{90}Y-labeled ibritumomab tiuxetan (Zevalin) is also a CD20-reactive antibody with activity in non-Hodgkin's lymphoma. The first step in the treatment regimen is imaging of ^{111}I-labeled ibritumomab tiuxetan combined with the unlabeled antibody, which is administered following rituximab, a nonradioactive antibody of the same reactivity to CD20 antigen. A therapeutic dose of ^{90}Y-labeled ibritumomab tiuxetan is then given together with the unlabeled antibody. Compared with ^{131}I, the advantages of ^{90}Y include its significantly better imaging characteristics and the improved radiation safety for health care workers. Although the products have not been directly compared, equivalent long-term response rates for ^{90}Y-labeled ibritumomab tiuxetan and ^{131}I-labeled tositumomab are reported in patients with non-Hodgkin's lymphoma (168). These radiolabeled antibody therapies are actively being studied in non-Hodgkin's lymphoma, and novel agents targeting CD22, CD80, and other antigens are being developed.

Third-generation products for radioimmunodetection and targeted radiotherapy may be able to take advantage of key advances in targeting technology, such as multistep techniques (169, 170). One such example that has recently been applied to CEA imaging in preclinical validation tests is pretargeting, which addresses the limitation of the slow blood clearance of IgG. The technique involves signal amplification of the radiotracer *in situ* by pretargeting a multivalent, bispecific antibody with reactivity to both CEA and a small compound to which the radionuclide is attached (171). Improved imaging methods, such as PET, as well as labeling with near-IR-emitting fluorochromes also offer advantages (172–174), and rapid imaging using pretargeting and other techniques could enable application of PET radionuclides with short half-lives (e.g., ^{18}F

Downloaded from clincancerres.aacrjournals.org on April 5, 2013. © 2005 American Association for Cancer Research.

and ^{68}Ga). A spectrum of antibodies and antibody derivatives, including minibodies and diabodies (175, 176), are now available based on advanced molecular engineering techniques, and these forms are likely to have targeting advantages when optimized. These new antibody forms are also likely to lack immunogenicity, permitting repeated diagnostic use, or therapeutic administration (177). Other possible applications include assessment of drug pharmacodynamics and treatment response based on *in vivo* antigen detection (178). In some cancers, particularly leukemias and lymphomas, α-emitters with higher linear energy transfer rates may join β-emitters (179, 180). These diverse advances in the technology of imaging and radiolabeling, and in molecular engineering of antibodies, will together provide opportunities to develop increasingly effective molecularly targeted agents for imaging and therapy.

Opportunities for Probe Development and Testing: Development Path and Regulations

Imaging probe discovery and development is an active area of research, with many examples of promising probes that are being, or will be, applied to improve cancer patient management and facilitate oncologic drug development. As described in the FDA Critical Path Initiative, imaging probes and technologies represent an especially important drug development tool, with particular utility for accelerating the clinical evaluation of molecularly targeted therapies for cancer and other diseases. Much recent attention and effort has focused on the regulatory mechanisms relevant to the clinical study and approval of imaging probes. Imaging probes are regulated as drugs by the FDA, and the primary mechanism for new imaging probe development and testing is the IND application specified in 21 CFR §312; FDA recently updated its 1998 draft guidance regarding the development of imaging drug and biological products for approval indications.[15] Limited enrollment, basic science clinical research projects with radiolabeled drugs, and imaging probes that are not new molecular entities can also be conducted in a non-IND setting as per the RDRC regulations set forth in 21 CFR §361.1. (Generally, a "new molecular entity" is an agent that has not previously been tested in humans.)

FDA has recognized that the traditional design of first-in-humans trials, which are intended to facilitate rapid ascertainment of dose-limiting toxicity and movement into Phase 2 testing, is not well suited for low-dose imaging, pharmacokinetic or pharmacodynamic assessments. Early information from such exploratory trials may significantly improve the subsequent drug development program. Therefore, FDA has developed draft guidance regarding exploratory (early Phase 1) clinical trials of new molecular entities conducted under the IND regulations.[12] The guidance addresses approaches consistent with the flexibility of the IND regulations (21 CFR §312) regarding initial clinical testing in exploratory studies. Specifically, guidance is provided on the types and amount of preclinical data and chemistry, manufacturing, and controls information needed for IND applications if an exploratory study of limited expected exposure and duration (e.g., 7 days) is planned. In keeping with the FDA Critical Path Initiative, the FDA draft guidance aims to reduce barriers to initial clinical testing of promising agents and to decrease the resources required to develop agents with a higher potential risk of failure. The FDA guidance outlines several exploratory clinical study designs and the attendant preclinical data requirements as examples; additional approaches that are consistent with the IND regulations could be developed for specific needs.

For imaging probes, preclinical toxicology studies, chemistry, manufacturing, and controls requirements, and attendant scaleup synthesis are the greatest perceived hurdles to development and early clinical testing. In addition, because preclinical studies cannot always predict the clinical potential of an imaging probe, early exploratory clinical testing (including comparisons among multiple related candidates) is critical for early go/no-go decisions. Thus, microdosing and other exploratory studies provide an especially important opportunity for the development of novel imaging probes. For imaging agents that are not new molecular entities [i.e., agents with prior human exposure either endogenously or exogenously (e.g., drugs studied under a prior IND)], basic scientific research questions can be addressed in small clinical studies under the RDRC regulations. In addition, such established imaging probes can play a valuable role in several types of exploratory studies of novel oncologic drug products. The following sections discuss the U.S. regulations and draft guidances addressing the IND and non-IND pathways pertinent to early clinical imaging probe development. The European Agency for the Evaluation of Medicinal Products position article regarding the nonclinical safety studies required to support clinical microdose studies is also considered.

Exploratory studies

Imaging probe development using exploratory studies. Before the conduct of traditional dose escalation and safety studies during drug development, exploratory studies can provide early indications of the feasibility or promise of new molecular entities. Exploratory studies are defined as those of limited duration (e.g., 7 days) and drug exposure that are without therapeutic intent; one example is a study of a novel agent at a microdose (i.e., less than one-hundredth of the calculated pharmacologic dose, with a maximum of 100 μg). The goals of exploratory studies may include pharmacokinetic or pharmacodynamic evaluation, characterization of a new therapeutic target, or comparative study of several promising candidates designed to interact with a particular target. Exploratory studies have the potential to improve the efficiency of early drug or imaging probe development in several ways. For example, compared with the standard approach to Phase 1 clinical testing, exploratory studies require substantially fewer subjects and a greatly decreased amount of test article. Thus, their use can significantly reduce the timeline and costs for drug or imaging probe development. Exploratory studies also provide an avenue for exploring and validating promising novel targets and approaches that have a high associated risk of failure. Importantly, because such failures can be detected early in the development process, exploratory studies can limit human exposure to unsuccessful candidates. In addition, appropriately applied exploratory studies have the potential to improve the quality of drugs, biologics, and imaging probes that continue to the later, more costly and extensive stages of testing and development.

[15] Guidance for industry: developing medical imaging drugs and biologics. http://www.fda.gov/cber/gdlns/medimagesaf.pdf. Department of Health and Human Services. Accessed March 14, 2005.

Downloaded from clincancerres.aacrjournals.org on April 5, 2013. © 2005 American Association for Cancer Research.

FDA recently developed guidance seeking to clarify example clinical approaches and attendant preclinical study requirements for exploratory studies under the IND regulations (21 CFR §312).[12] The content of the IND will be less extensive; for example, it would not be necessary to detail the overall agent development plan. A summary report of chemistry, manufacturing, and controls information should be provided, and chemistry signals suggestive of potential human risk, including proposed measures to monitor such risk, should be discussed. A separate draft guidance on manufacturing controls is also under development by the FDA. As envisioned in the exploratory IND guidance, the requirements for supporting preclinical toxicology testing would be tailored to address the expected human exposure in the proposed exploratory study; both single-dose and multiple-dose clinical study designs will be included. For microdosing studies, including the study of a single microdose of novel clinical imaging probes, an extended single-dose 14-day toxicology testing using the intended clinical route of administration would be considered sufficient. One mammalian species can be used if justified by supporting *in vitro* data. Standard end points (i.e., body weights, clinical signs, histopathology, and hematology assessments) would be required at an interim time point (typically 2 days) as well as at study end. The toxicology study should establish either the minimal toxic effect or the safety of a 100-fold higher dose than the proposed human dose. Standard genetic toxicology testing would not be required.

The European Agency for the Evaluation of Medicinal Products specifies somewhat different preclinical toxicology testing requirements to support exploratory (pre-Phase 1) clinical testing of a single microdose (e.g., of a radiotracer). As addressed in their 2004 position article,[16] the recommendations include an extended single-dose toxicity study in both sexes of a single mammalian species with i.v. administration (and the intended clinical route, if different). Histopathology and hematology assessments would be required at two time points, 2 and 14 days after the single administration. Standard genotoxicity studies would be required for most agents, but abridged versions of the Ames and other (chromosome aberration, mouse lymphoma, or *in vitro* micronucleus) tests would suffice if the agent class is known to lack genotoxicity.

Application of imaging probes in exploratory clinical studies of oncologic drug or biological products. After initial characterization, imaging agents have significant potential to facilitate the conduct of other types of exploratory studies described in the FDA draft guidance, particularly for the evaluation of oncologic agents. These include exploratory clinical investigations of the mechanisms of action of new oncologic drug or biological products. For the therapeutic drug proposed for such studies, short-term mechanism-based supporting studies in two (or in some cases, one) animal species would be acceptable. For example, the clinical starting dose could be selected based on the preclinical dose and regimen required to achieve a relevant phamacodynamic end point (e.g., receptor occupancy or enzyme inhibition). Characterization of the preclinical toxicologic profile by standard approaches (e.g., hematology and histopathology) of all tested doses would be appropriate. Application of imaging probes and technology could facilitate the pharmacologic measures of activity during preclinical testing. Moreover, such use would validate application of the same probes or technology in the exploratory clinical testing of the drug. Simultaneous use of two imaging probes to assess both the drug effect on the molecular target (e.g., EGFR) and its ultimate effect on the tumor (e.g., proliferation using FLT) would be especially valuable for these early assessments, including comparisons among agents within a given class.

Imaging agents could also facilitate exploratory single-dose or multiple-dose studies designed to elicit pharmacologic effects of novel drugs. Unlike typical Phase 1 safety and tolerance studies, these exploratory clinical studies would not entail dose-escalation to the maximally tolerated dose. Thus, in contrast to those required to support traditional IND applications, toxicology studies would not define the maximally tolerated dose. Instead, the goal would be to establish the no observed adverse effect level, which would serve as the basis for defining the clinical starting dose (e.g., as one-fiftieth of no observed adverse effect level). The no observed adverse effect level would be derived in a 14-day toxicology study with toxicokinetic evaluations in the rat or other species confirmed to be sensitive to the test article. The clinical stopping doses could also be defined by the rat no observed adverse effect level, by the preclinical area under the curve, from clinical signs, or by establishment of pharmacologic effect or target modulation. Unless the clinical trial will only enroll individuals with limited life expectancy, as may be the case for exploratory testing of oncologic drug products, genetic toxicology testing should also be done. If applied in preclinical testing, single or dual imaging probes could play a significant role in characterizing the pharmacologic and toxicologic sensitivity to the test agent. Such information could be valuable in the design and implementation of the exploratory clinical trial.

FDA guidance is advisory and does not set requirements. Thus, the exploratory IND guidance is intended to provide examples of the inherent flexibility of the current regulations and to encourage use of this flexibility in early clinical investigations.

Radioactive drug research committee

Since the adoption of the RDRC regulations in 1975, basic clinical research using radioactive drugs that are generally recognized as safe and effective can be conducted without an IND. Such studies are conducted under FDA-approved institutional RDRCs that are qualified to review the technical and scientific merits of the research protocol. As described in 21 CFR §361.1(c)(1), the RDRC should include a physician specializing in nuclear medicine, with four or more other members contributing expertise, respectively, in radioactive drug formulation, radiation safety, dosimetry, and other relevant areas (radiology, internal medicine, endocrinology, radiation therapy, etc.). The RDRCs provide annual reports [per 21 CFR §361.1(c)(3)] to FDA detailing the committee membership as well as summarizing conducted studies. Research study approval [per 21 CFR §361.1(b)(1)(iv)] is dependent on study investigator qualifications, proper licensure of the medical facility for clinical radioactive drug use, and appropriate quality assurance testing of the radioactive drug. The regulations specify a limited radiation dose that should be justified by the research quality and significance. The protocol should include appropriately

[16] Position article on nonclinical safety studies to support clinical trials with a singe microdose. http://www.emea.eu.int/pdfs/human/swp/259902en.pdf. European Agency for the Evaluation of Medicinal Products. Accessed March 14, 2005.

Downloaded from clincancerres.aacrjournals.org on April 5, 2013. © 2005 American Association for Cancer Research.

selected and consented study subjects, be of sound design, and also be institutional review board approved. Adverse events must be reported by the investigator to the RDRC [per 21 CFR §361.1(d)(8)].

As specified in 21 CFR §361.1, RDRC research is for basic science purposes; excluded are studies for immediate therapeutic or diagnostic intent, individual patient decision-making, and safety or effectiveness determinations. Although exploration of the metabolism (e.g., pharmacokinetics) of the radioactive drug is permitted, the dose to be administered must lack any clinically detectable pharmacologic effects [per 21 CFR §361.1(b)(2)]. Because published data or prior clinical studies are needed to show the absence of a pharmacologic effect, first-in-human studies are not done under the RDRC regulations. Well-characterized drugs that have been labeled by addition of, or substitution with, a radionuclide (e.g., ^{18}F) are considered on a case-by-case basis by the individual RDRCs, which may require additional preclinical data to show a comparable pharmacologic or toxicologic profile of the labeled drug to the parent molecule. Pediatric studies usually require an IND and are excluded in the RDRC regulations, except under certain circumstances, and when allowed must comply with the minimal risk and other considerations regarding vulnerable populations specified in 21 CFR 50 Subpart D. Special reporting requirements apply to studies in children and to all studies involving >30 subjects.

Thus, RDRC studies are useful to answer basic research questions during drug development, but not all clinical studies required for full development can be done. RDRC research generally falls into two categories: metabolism and excretion analyses (e.g., using ^{14}C, ^{3}H, and other radiotracers in mass balance determinations) and imaging studies (noninvasive functional as well as molecular imaging). In 2003, >80 FDA-approved RDRCs were active, approving >280 studies with ~3,000 subjects. Of the 120 different compounds used, 77% were positron-emitting imaging nuclides and a further 4.5% were γ-emitters used in imaging (including ^{99m}Tc, ^{123}I, and ^{131}I). Together, imaging studies comprise ~80% of RDRC investigations. Examples include imaging research projects regarding biodistribution, pathophysiology (e.g., tumor uptake), receptor binding or occupancy, transport processes, enzyme activity, and processes, such as apoptosis, DNA synthesis, and cellular proliferation. In addition, radiotracers can be used simultaneously with approved drugs in RDRC studies.

Summary

Imaging probes have great potential to facilitate all stages of oncologic drug development, particularly for molecularly targeted agents. The discovery and development of imaging probes is an active research area, and the exploratory IND guidance provides an important opportunity to improve the efficiency of initial clinical testing of promising probes. Once pilot studies have been conducted and clinical performance characteristics of the imaging probe are obtained, the imaging probe can then be applied in a research setting as a biomarker tool in the early clinical investigation of new oncologic therapeutics. Early pharmacokinetic and pharmacodynamic assessments are of particular value in translational research studies for new targeted agents and other novel approaches with promising rationale or preclinical data but also with an inherently high risk of failure. Because they require substantially fewer subjects and a greatly decreased amount of test substance, exploratory studies using imaging probes can reduce the time, costs, and other resources of developing unsuccessful candidates and can limit human exposure to them. This could result in an overall enrichment in the quality of therapeutics that continue in the drug development pipeline.

Several strategies can be envisioned for applying imaging probes in the first-in-human testing settings described in the exploratory IND guidance. For example, the performance characteristics of a proliferation probe (e.g., FLT; ref. 181) could be established in an exploratory clinical validation study measuring proliferation by proliferating cell nuclear antigen or Ki-67 staining. The probe could then be applied to select or stratify patients likely to respond and/or as an efficacy biomarker (e.g., in a first-in-human study of a novel antiproliferative chemotherapeutic conducted under an exploratory IND). As illustrated in Fig. 3, FLT could also be applied in combination with a second PET imaging probe that enables visualization of the molecular target of a novel chemotherapeutic that is expected to decrease tumor proliferation. Another possibility is to employ a targeted probe and FLT in tandem; patients could be selected based on presence or quantity of the molecular target of the drug using one imaging probe, with FLT applied serially as a pharmacodynamic marker. FLT could also be compared with other proliferation probes [1-(2′-deoxy-2′-fluoro-β-D-arabinofuranosyl) thymine, 2′-deoxy-2′-fluoro-5-fluoro-1-β-D-arabinofuranosyluracil, etc.] in an exploratory study of one or several promising candidate drugs or biologics, with the goal of selecting the best combination of probe and therapeutic for further development. These and other approaches for applying molecular probes in the early stages of drug development would provide valuable data that can be used in go/no-go decision-making for chemotherapeutics.

The following summarizes scientific and regulatory considerations for the development and application of probes in oncology and provides recommendations to further progress in this area.

- The FDA Critical Path Initiative outlines the need for modernization of the medical product development process, particularly with regard to the tools for assessing safety and efficacy. Molecular imaging probes that leverage recent scientific advances in genomics, proteomics, metabolomics, and materials science have great potential as oncologic drug development tools. Examples of the imaging probes under study in oncology include those for fundamental neoplastic processes (apoptosis, proliferation, angiogenesis, hypoxia, etc.) and for prominent molecular targets (e.g., receptors, proteases, and other enzymes). Others can refine cancer staging. Appropriately applied, imaging-based biomarkers

  Identify, characterize, and validate therapeutic targets;
  Screen and optimize candidate targeted agents;
  Provide proof-of-concept for agents and models;
  Enhance mechanistic understanding of drug or drug combination effects (e.g., target engagement, modification, cell death, or tumor vitality);
  Identify, stratify, and enrich study and patient populations;
  Rapidly and noninvasively assess response, resistance, and toxicity; and
  Correlate response with clinical outcome.

Downloaded from clincancerres.aacrjournals.org on April 5, 2013. © 2005 American Association for Cancer Research.

and surrogate end points can play a valuable role throughout drug development as tools to:

- FDA recently developed a draft guidance document detailing example early clinical testing settings feasible under the existing IND regulations (21 CFR §312). The described exploratory settings are especially relevant for first-in-human studies with imaging probes. Microdosing studies with novel imaging probes provide an opportunity for early assessment of pharmacokinetic variables and other probe characteristics. Importantly, such exploratory studies would require only limited supporting preclinical data. The required preclinical safety testing would focus on identifying measurable risks from exposure in the planned studies rather than defining theoretical or extrapolated risks. In addition, the amount of chemistry, manufacturing, and controls data as well as the IND content would also be reduced compared with that needed for traditional phase I clinical testing.
- Initial clinical studies under the exploratory mechanism could provide sufficient validation of the imaging probe so that it could be accepted and implemented as a biomarker tool for assessing oncologic drug activity. Thus, even at an early development stage, the imaging probe could be applied to accelerate drug development. Example applications include, as described above for FLT, the significant potential of imaging probes for facilitating the conduct of first-in-human studies of promising novel chemotherapeutics and other agents. Close integration of imaging probe and drug development throughout preclinical testing and validation can furnish robust mechanistic end points for clinical testing of novel agents.
- Another avenue for applying imaging probes in oncologic drug research is the RDRC regulations (21 CFR §361.1). Although not for initial testing of new molecular entities, the RDRC provides a non-IND mechanism for small basic research studies using approved agents and investigational imaging probes. In November 2004, FDA convened a public meeting to consider changes and updates to the RDRC regulations as set forth in 21 CFR §361.1.[17] Specifically, the topics considered included the following: (*a*) radiation dose limits for adults, (*b*) pediatric study safety, (*c*) quality and purity of radiopharmaceuticals, (*d*) exclusion of pregnant women, and (*e*) RDRC membership and administrative issues. A FDA draft guidance addressing these and other issues (e.g., chemistry, manufacturing, and controls requirements) pertaining to research conduct under the RDRC is anticipated.
- In addition to generating valuable imaging tools with more immediate application in oncologic drug development, initial exploratory and basic research studies can also play a role in the selection and prioritization of candidate imaging probes for more rigorous, continued development. Indeed, preliminary data from exploratory studies can inform the design of the Phase 1 to 3 trials that would ultimately lead to marketing approval of probes intended to diagnose and monitor diseases. This rigorous development of imaging agents for disease diagnosis and monitoring is addressed in the June 2004 update to the 1998 draft guidance.[15] The three-part 2004 guidance considers safety assessments and clinical indications as well as the design, analysis, and interpretation of clinical studies.
- Challenges for developing molecularly targeted probes include obtaining adequate intracellular delivery and acceptable signal-to-noise amplification to obtain accurate information about targets with low (nanomolar to micromolar) concentrations. Instability and *in vivo* metabolism of the radiotracer can limit targeting and result in normal tissue toxicity. In addition, the large molecules and peptides that can serve as substrates for cellular receptors of high interest (e.g., EGFR and VEGF receptor) are readily degraded and can cause immunogenic reactions. Antibody probes can be limited by slow and uneven tissue antigen targeting, cross-reactivity with normal tissue antigens, and complex and biologically based production methods. Approaches being explored include applying multistep procedures to improve antibody targeting (e.g., pretargeting) and using small peptides, peptide fragments, and antibody forms (e.g., minibodies and diabodies). For small molecules, novel synthesis techniques (e.g., click chemistry) can improve targeting. Other strategies are focused on developing lower thresholds of detection, employing multivalency to improve target affinity, and applying cellular internalization and trapping techniques of imaging ligands.
- To foster the continued discovery and development of imaging probes with value in oncology, cooperation is needed between imaging science and molecular target discovery efforts in cancer genomics, proteomics, and metabolomics. Better integration of oncologic drug and imaging probe development is also necessary. Partnerships among FDA, National Cancer Institute, Centers for Medicare and Medicaid Services, industry, and academic scientists should be encouraged. Collaborative studies could provide validation of imaging probes and associated end points in preclinical models. These efforts could also include the early clinical testing of imaging probes and their application as tools to accelerate oncologic drug development.

[17] Amended transcript. November 2004 public meeting. Radioactive drugs for certain uses. http://www.fda.gov/cder/meeting/clinicalResearch/amendedtranscript.pdf. Department of Health and Human Services. Accessed March 14, 2005.

References

1. Albanell J, Baselga J. Trastuzumab, a humanized anti-HER2 monoclonal antibody, for the treatment of breast cancer. Drugs Today (Barc) 1999;35:931–46.
2. Radford IR. Imatinib. Novartis. Curr Opin Investig Drugs 2002;3:492–9.
3. Dowell J, Minna JD, Kirkpatrick P. Erlotinib hydrochloride. Nat Rev Drug Discov 2005;4:13–4.
4. Kane RC, Bross PF, Farrell AT, et al. Velcade: U.S. FDA approval for the treatment of multiple myeloma progressing on prior therapy. Oncologist 2003;8:508–13.
5. Cunningham D, Humblet Y, Siena S, et al. Cetuximab monotherapy and cetuximab plus irinotecan in irinotecan-refractory metastatic colorectal cancer. N Engl J Med 2004;351:337–45.
6. Erlichman C, Sargent DJ. New treatment options for colorectal cancer. N Engl J Med 2004;351:391–2.
7. Cohen MH, Johnson JR, Li N, et al. Approval summary: letrozole in the treatment of postmenopausal women with advanced breast cancer. Clin Cancer Res 2002;8:665–9.
8. Kelloff GJ, Sigman CC. New science-based endpoints to accelerate oncology drug development. Eur J Cancer 2005;41:491–501.
9. Park JW, Kerbel RS, Kelloff GJ, et al. Rationale for biomarkers and surrogate end points in mechanism-driven oncology drug development. Clin Cancer Res 2004;10:3885–96.
10. Paez JG, Janne PA, Lee JC, et al. EGFR mutations in lung cancer: correlation with clinical response to gefitinib therapy. Science 2004;304:1497–500.
11. Pao W, Miller V, Zakowski M, et al. EGF receptor gene mutations are common in lung cancers from "never smokers" and are associated with sensitivity of tumors to gefitinib and erlotinib. Proc Natl Acad Sci U S A 2004;101:13306–11.
12. Lynch TJ, Bell DW, Sordella R, et al. Activating mutations in the epidermal growth factor receptor

Downloaded from clincancerres.aacrjournals.org on April 5, 2013. © 2005 American Association for Cancer Research.

underlying responsiveness of non-small-cell lung cancer to gefitinib. N Engl J Med 2004;350:2129–39.
13. Shigematsu H, Lin L, Takahashi T, et al. Clinical and biological features associated with epidermal growth factor receptor gene mutations in lung cancers. J Natl Cancer Inst 2005;97:339–46.
14. Sellers WR, Meyerson M. EGFR gene mutations: a call for global x global views of cancer. J Natl Cancer Inst 2005;97:326–8.
15. Rudin M, Weissleder R. Molecular imaging in drug discovery and development. Nat Rev Drug Discov 2003;2:123–31.
16. Combes RD, Berridge T, Connelly J, et al. Early microdose drug studies in human volunteers can minimise animal testing. Proceedings of a workshop organised by Volunteers in Research and Testing. Eur J Pharm Sci 2003;19:1–11.
17. Barrio JR, Marcus CS, Hung JC, et al. A rational regulatory approach for positron emission tomography imaging probes: from "first in man" to NDA approval and reimbursement. Mol Imaging Biol 2004; 6:361–7.
18. Weissleder R, Ntziachristos V. Shedding light onto live molecular targets. Nat Med 2003;9:123–8.
19. Lanza GM, Wickline SA. Targeted ultrasonic contrast agents for molecular imaging and therapy. Curr Probl Cardiol 2003;28:625–53.
20. Lindner JR. Molecular imaging with contrast ultrasound and targeted microbubbles. J Nucl Cardiol 2004;11:215–21.
21. Manetsch R, Krasinski A, Radic Z, et al. *In situ* click chemistry: enzyme inhibitors made to their own specifications. J Am Chem Soc 2004;126:12809–18.
22. Kolb HC, Sharpless KB. The growing impact of click chemistry on drug discovery. Drug Discov Today 2003;8:1128–37.
23. Bonasera TA, Ortu G, Rozen Y, et al. Potential (18) F-labeled biomarkers for epidermal growth factor receptor tyrosine kinase. Nucl Med Biol 2001;28:359–74.
24. Ortu G, Ben-David I, Rozen Y, et al. Labeled EGFr-TK irreversible inhibitor (ML03): *in vitro* and *in vivo* properties, potential as PET biomarker for cancer and feasibility as anticancer drug. Int J Cancer 2002;101:360–70.
25. Mishani E, Abourbeh G, Rozen Y, et al. Novel carbon-11 labeled 4-dimethylamino-but-2-enoic acid [4-(phenylamino)-quinazoline-6-yl]-amides: potential PET bioprobes for molecular imaging of EGFR-positive tumors. Nucl Med Biol 2004;31:469–76.
26. Fabian MA, Biggs WH III, Treiber DK, et al. A small molecule-kinase interaction map for clinical kinase inhibitors. Nat Biotechnol 2005;23:329–36.
27. Yuan H, Luo J, Field S, et al. Synthesis and activity of C11-modified wortmannin probes for PI3 kinase. Bioconjug Chem 2005;16:669–75.
28. Joyce JA, Baruch A, Chehade K, et al. Cathepsin cysteine proteases are effectors of invasive growth and angiogenesis during multistage tumorigenesis. Cancer Cell 2004;5:443–53.
29. Joyce JA, Hanahan D. Multiple roles for cysteine cathepsins in cancer. Cell Cycle 2004;3:1516–619.
30. DeClerck YA, Mercurio AM, Stack MS, et al. Proteases, extracellular matrix, and cancer: a workshop of the path B study section. Am J Pathol 2004; 164:1131–9.
31. Weissleder R, Tung CH, Mahmood U, et al. *In vivo* imaging of tumors with protease-activated near-infrared fluorescent probes. Nat Biotechnol 1999;17: 375–8.
32. Kaelin WG, Jr. Choosing anticancer drug targets in the postgenomic era. J Clin Invest 1999;104:1503–6.
33. Shields AF, Mankoff D, Graham MM, et al. Analysis of 2-carbon-11-thymidine blood metabolites in PET imaging. J Nucl Med 1996;37:290–6.
34. Wells P, Aboagye E, Gunn RN, et al. 2-[^{11}C]Thymidine positron emission tomography as an indicator of thymidylate synthase inhibition in patients treated with AG337. J Natl Cancer Inst 2003;95:675–82.
35. Blasberg RG, Roelcke U, Weinreich R, et al. Imaging brain tumor proliferative activity with [^{124}I]iododeoxyuridine. Cancer Res 2000;60:624–35.
36. Carnochan P, Brooks R. Radiolabelled 5′-iodo-2′-deoxyuridine: a promising alternative to [^{18}F]-2-fluoro-2-deoxy-D-glucose for PET studies of early response to anticancer treatment. Nucl Med Biol 1999;26:667–72.
37. Conti PS, Alauddin MM, Fissekis JR, et al. Synthesis of 2′-fluoro-5-[^{11}C]-methyl-1-β-D-arabinofuranosyluracil ([^{11}C]-FMAU): a potential nucleoside analog for *in vivo* study of cellular proliferation with PET. Nucl Med Biol 1995;22:783–9.
38. Alauddin MM, Shahinian A, Park R, et al. Synthesis and evaluation of 2′-deoxy-2′-^{18}F-fluoro-5-fluoro-1-β-D-arabinofuranosyluracil as a potential PET imaging agent for suicide gene expression. J Nucl Med 2004; 45:2063–9.
39. Shields AF, Grierson JR, Dohmen BM, et al. Imaging proliferation *in vivo* with [F-18]FLT and positron emission tomography. Nat Med 1998;4:1334–6.
40. Krohn KA, Mankoff DA, Eary JF. Imaging cellular proliferation as a measure of response to therapy. J Clin Pharmacol 2001;Suppl:96–103S.
41. Shields AF. PET imaging with ^{18}F-FLT and thymidine analogs: promise and pitfalls. J Nucl Med 2003;44: 1432–4.
42. Pinder SE, Wencyk P, Sibbering DM, et al. Assessment of the new proliferation marker MIB1 in breast carcinoma using image analysis: associations with other prognostic factors and survival. Br J Cancer 1995;71:146–9.
43. Muzi M, Mankoff DA, Grierson JR, et al. Kinetic modeling of 3′-deoxy-3′-fluorothymidine in somatic tumors: mathematical studies. J Nucl Med 2005;46: 371–80.
44. Muzi M, Vesselle H, Grierson JR, et al. Kinetic analysis of 3′-deoxy-3′-fluorothymidine PET studies: validation studies in patients with lung cancer. J Nucl Med 2005;46:274–82.
45. Hajra KM, Liu JR. Apoptosome dysfunction in human cancer. Apoptosis 2004;9:691–704.
46. Hersey P, Zhang XD. Overcoming resistance of cancer cells to apoptosis. J Cell Physiol 2003;196:9–18.
47. Knudson AG. Cancer genetics. Am J Med Genet 2002;111:96–102.
48. Hill MM, Adrain C, Martin SJ. Portrait of a killer: the mitochondrial apoptosome emerges from the shadows. Mol Interv 2003;3:19–26.
49. Schlegel RA, Williamson P. Phosphatidylserine, a death knell. Cell Death Differ 2001;8:551–63.
50. Belhocine T, Steinmetz N, Hustinx R, et al. Increased uptake of the apoptosis-imaging agent (99m)Tc recombinant human Annexin V in human tumors after one course of chemotherapy as a predictor of tumor response and patient prognosis. Clin Cancer Res 2002;8:2766–74.
51. Kemerink GJ, Liu X, Kieffer D, et al. Safety, biodistribution, and dosimetry of ^{99m}Tc-HYNIC-Annexin V, a novel human recombinant Annexin V for human application. J Nucl Med 2003;44:947–52.
52. Glaser M, Collingridge DR, Aboagye EO, et al. Iodine-124 labelled Annexin-V as a potential radiotracer to study apoptosis using positron emission tomography. Appl Radiat Isot 2003;58:55–62.
53. Grierson JR, Yagle KJ, Eary JF, et al. Production of [F-18]fluoroannexin for imaging apoptosis with PET. Bioconjug Chem 2004;15:373–9.
54. Yagle KJ, Eary JF, Tait JF, et al. Evaluation of ^{18}F-Annexin V as a PET imaging agent in an animal model of apoptosis. J Nucl Med 2005;46:658–66.
55. Petrovsky A, Schellenberger E, Josephson L, et al. Near-infrared fluorescent imaging of tumor apoptosis. Cancer Res 2003;63:1936–42.
56. Schellenberger EA, Bogdanov A, Jr., Hogemann D, et al. Annexin V-CLIO: a nanoparticle for detecting apoptosis by MRI. Mol Imaging 2002;1:102–7.
57. Schellenberger EA, Bogdanov A, Jr., Petrovsky A, et al. Optical imaging of apoptosis as a biomarker of tumor response to chemotherapy. Neoplasia 2003; 5:187–92.
58. Schellenberger EA, Sosnovik D, Weissleder R, et al. Magneto/optical Annexin V, a multimodal protein. Bioconjug Chem 2004;15:1062–7.
59. Schellenberger EA, Weissleder R, Josephson L. Optimal modification of Annexin V with fluorescent dyes. Chembiochem 2004;5:271–4.
60. Roy N, Deveraux QL, Takahashi R, et al. The c-IAP-1 and c-IAP-2 proteins are direct inhibitors of specific caspases. EMBO J 1997;16:6914–25.
61. Deveraux QL, Reed JC. IAP family proteins-suppressors of apoptosis. Genes Dev 1999;13:239–52.
62. Lahorte CM, Vanderheyden JL, Steinmetz N, et al. Apoptosis-detecting radioligands: current state of the art and future perspectives. Eur J Nucl Med Mol Imaging 2004;31:887–919.
63. Reed JC, Pellecchia M. Apoptosis-based therapies for hematological malignancies. Blood 2005;106: 408–18.
64. Folkman J. Role of angiogenesis in tumor growth and metastasis. Semin Oncol 2002;29:15–8.
65. Miller JC, Pien HH, Sahani D, et al. Imaging angiogenesis: applications and potential for drug development. J Natl Cancer Inst 2005;97:172–87.
66. Boxerman JL, Hamberg LM, Rosen BR, et al. MR contrast due to intravascular magnetic susceptibility perturbations. Magn Reson Med 1995;34:555–66.
67. Dennie J, Mandeville JB, Boxerman JL, et al. NMR imaging of changes in vascular morphology due to tumor angiogenesis. Magn Reson Med 1998;40:793–9.
68. Bremer C, Mustafa M, Bogdanov A, Jr., et al. Steady-state blood volume measurements in experimental tumors with different angiogenic burdens a study in mice. Radiology 2003;226:214–20.
69. Tropres I, Grimault S, Vaeth A, et al. Vessel size imaging. Magn Reson Med 2001;45:397–408.
70. Callahan RJ, Bogdanov A, Jr., Fischman AJ, et al. Preclinical evaluation and phase I clinical trial of a ^{99m}Tc-labeled synthetic polymer used in blood pool imaging. AJR Am J Roentgenol 1998;171:137–43.
71. Bogdanov AA, Lewin M, Weissleder R. Approaches and agents for imaging the vascular system. Adv Drug Deliv Rev 1999;37:279–93.
72. Pasqualini R, Koivunen E, Ruoslahti E. α_V Integrins as receptors for tumor targeting by circulating ligands. Nat Biotechnol 1997;15:542–6.
73. Falcioni R, Antonini A, Nistico P, et al. $\alpha_6\beta_4$ and $\alpha_6\beta_1$ Integrins associate with ErbB-2 in human carcinoma cell lines. Exp Cell Res 1997;236:76–85.
74. Cheresh DA, Pytela R, Pierschbacher MD, et al. An Arg-Gly-Asp-directed receptor on the surface of human melanoma cells exists in an divalent cation-dependent functional complex with the disialoganglioside GD2. J Cell Biol 1987;105:1163–73.
75. Chen X, Park R, Shahinian AH, et al. ^{18}F-Labeled RGD peptide: initial evaluation for imaging brain tumor angiogenesis. Nucl Med Biol 2004;31: 179–89.
76. Haubner R, Wester HJ, Weber WA, et al. Noninvasive imaging of $\alpha(v)\beta_3$ integrin expression using ^{18}F-labeled RGD-containing glycopeptide and positron emission tomography. Cancer Res 2001;61:1781–5.
77. Ogawa M, Hatano K, Oishi S, et al. Direct electrophilic radiofluorination of a cyclic RGD peptide for *in vivo* $\alpha(v)\beta_3$ integrin related tumor imaging. Nucl Med Biol 2003;30:1–9.
78. Poethko T, Schottelius M, Thumshirn G, et al. Two-step methodology for high-yield routine radiohalogenation of peptides: (18)F-labeled RGD and octreotide analogs. J Nucl Med 2004;45:892–902.
79. Wang W, Ke S, Wu Q, et al. Near-infrared optical imaging of integrin $\alpha_v\beta_3$ in human tumor xenografts. Mol Imaging 2004;3:343–51.
80. Schmieder AH, Winter PM, Caruthers SD, et al. Molecular MR imaging of melanoma angiogenesis with $\alpha_v\beta_3$-targeted paramagnetic nanoparticles. Magn Reson Med 2005;53:621–7.
81. Sipkins DA, Cheresh DA, Kazemi MR, et al. Detection of tumor angiogenesis *in vivo* by $\alpha_V\beta_3$-targeted magnetic resonance imaging. Nat Med 1998;4:623–6.
82. Mulder WJ, Strijkers GJ, Griffioen AW, et al. A liposomal system for contrast-enhanced magnetic resonance imaging of molecular targets. Bioconjug Chem 2004;15:799–806.

Downloaded from clincancerres.aacrjournals.org on April 5, 2013. © 2005 American Association for Cancer Research.

83. Barber PA, Foniok T, Kirk D, et al. MR molecular imaging of early endothelial activation in focal ischemia. Ann Neurol 2004;56:116–20.

84. Kang HW, Weissleder R, Bogdanov A, Jr. Targeting of MPEG-protected polyamino acid carrier to human E-selectin *in vitro*. Amino Acids 2002;23:301–8.

85. Giaccia AJ, Simon MC, Johnson R. The biology of hypoxia: the role of oxygen sensing in development, normal function, and disease. Genes Dev 2004;18:2183–94.

86. Huang LE, Arany Z, Livingston DM, et al. Activation of hypoxia-inducible transcription factor depends primarily upon redox-sensitive stabilization of its α subunit. J Biol Chem 1996;271:32253–9.

87. Semenza GL. Involvement of hypoxia-inducible factor 1 in human cancer. Intern Med 2002;41:79–83.

88. Goda N, Dozier SJ, Johnson RS. HIF-1 in cell cycle regulation, apoptosis, and tumor progression. Antioxid Redox Signal 2003;5:467–73.

89. Brahimi-Horn C, Pouyssegur J. When hypoxia signalling meets the ubiquitin-proteasomal pathway, new targets for cancer therapy. Crit Rev Oncol Hematol 2005;53:115–23.

90. Guillemin K, Krasnow MA. The hypoxic response: huffing and HIFing. Cell 1997;89:9–12.

91. Jiang BH, Semenza GL, Bauer C, et al. Hypoxia-inducible factor 1 levels vary exponentially over a physiologically relevant range of O_2 tension. Am J Physiol 1996;271:C1172–80.

92. Hopfl G, Ogunshola O, Gassmann M. HIFs and tumors—causes and consequences. Am J Physiol Regul Integr Comp Physiol 2004;286:R608–23.

93. Coleman CN, Mitchell JB, Camphausen K. Tumor hypoxia: chicken, egg, or a piece of the farm? J Clin Oncol 2002;20:610–5.

94. Rajendran JG, Mankoff DA, O'Sullivan F, et al. Hypoxia and glucose metabolism in malignant tumors: evaluation by [^{18}F]fluoromisonidazole and [^{18}F]fluorodeoxyglucose positron emission tomography imaging. Clin Cancer Res 2004;10:2245–52.

95. Rajendran JG, Krohn KA. Imaging hypoxia and angiogenesis in tumors. Radiol Clin North Am 2005;43:169–87.

96. Rasey JS, Martin GV, Krohn KA. Quantifying hypoxia with radiolabeled fluoromisonidazole: pre-clinical and clinical studies. In: Machulla HJ, editor. Imaging of hypoxia: tracer developments. Dordrecht (the Netherlands): Kluwer Academic Publishers; 1999.

97. Wouters BG, van den Beucken T, Magagnin MG, et al. Targeting hypoxia tolerance in cancer. Drug Resist Updat 2004;7:25–40.

98. Becker A, Hansgen G, Bloching M, et al. Oxygenation of squamous cell carcinoma of the head and neck: comparison of primary tumors, neck node metastases, and normal tissue. Int J Radiat Oncol Biol Phys 1998;42:35–41.

99. Hockel M, Schlenger K, Knoop C, et al. Oxygenation of carcinomas of the uterine cervix: evaluation by computerized O_2 tension measurements. Cancer Res 1991;51:6098–102.

100. Brown JM. The hypoxic cell: a target for selective cancer therapy—Eighteenth Bruce F. Cain Memorial Award Lecture. Cancer Res 1999;59:5863–70.

101. Amellem O, Pettersen EO. Cell inactivation and cell cycle inhibition as induced by extreme hypoxia: the possible role of cell cycle arrest as a protection against hypoxia-induced lethal damage. Cell Prolif 1991;24:127–41.

102. Wilson WR. Tumor hypoxia: challenges for cancer chemotherapy. Cancer Biol Med 1992;3:87–131.

103. Brown JM. Tumor microenvironment and the response to anticancer therapy. Cancer Biol Ther 2002;1:453–8.

104. Lim JL, Berridge MS. An efficient radiosynthesis of [^{18}F]fluoromisonidazole. Appl Radiat Isot 1993;44:1085–91.

105. Graham MM, Peterson LM, Link JM, et al. Fluorine-18-fluoromisonidazole radiation dosimetry in imaging studies. J Nucl Med 1997;38:1631–6.

106. Dolbier WR, Jr., Li AR, Koch CJ, et al. [^{18}F]-EF5, a marker for PET detection of hypoxia: synthesis of precursor and a new fluorination procedure. Appl Radiat Isot 2001;54:73–80.

107. Tewson TJ. Synthesis of [^{18}F]fluoroetanidazole: a potential new tracer for imaging hypoxia. Nucl Med Biol 1997;24:755–60.

108. Barthel H, Wilson H, Collingridge DR, et al. *In vivo* evaluation of [^{18}F]fluoroetanidazole as a new marker for imaging tumour hypoxia with positron emission tomography. Br J Cancer 2004;90:2232–42.

109. Dearling JL, Lewis JS, Mullen GE, et al. Design of hypoxia-targeting radiopharmaceuticals: selective uptake of copper-64 complexes in hypoxic cells *in vitro*. Eur J Nucl Med 1998;25:788–92.

110. Lewis JS, McCarthy DW, McCarthy TJ, et al. Evaluation of ^{64}Cu-ATSM *in vitro* and *in vivo* in a hypoxic tumor model. J Nucl Med 1999;40:177–83.

111. Zanzonico P, O'Donoghue J, Chapman JD, et al. Iodine-124-labeled iodo-azomycin-galactoside imaging of tumor hypoxia in mice with serial microPET scanning. Eur J Nucl Med Mol Imaging 2004;31:117–28.

112. Ling CC, Humm J, Larson S, et al. Towards multidimensional radiotherapy (MD-CRT): biological imaging and biological conformality. Int J Radiat Oncol Biol Phys 2000;47:551–60.

113. Sledge GW, Jr., McGuire WL. Steroid hormone receptors in human breast cancer. Adv Cancer Res 1983;38:61–75.

114. Katzenellenbogen BS, Frasor J. Therapeutic targeting in the estrogen receptor hormonal pathway. Semin Oncol 2004;31:28–38.

115. Katzenellenbogen JA, Welch MJ, Dehdashti F. The development of estrogen and progestin radiopharmaceuticals for imaging breast cancer. Anticancer Res 1997;17:1573–6.

116. Seimbille Y, Rousseau J, Benard F, et al. ^{18}F-labeled difluoroestradiols: preparation and preclinical evaluation as estrogen receptor-binding radiopharmaceuticals. Steroids 2002;67:765–75.

117. Kiesewetter DO, Kilbourn MR, Landvatter SW, et al. Preparation of four fluorine-18-labeled estrogens and their selective uptakes in target tissues of immature rats. J Nucl Med 1984;25:1212–21.

118. Mintun MA, Welch MJ, Siegel BA, et al. Breast cancer: PET imaging of estrogen receptors. Radiology 1988;169:45–8.

119. Mankoff DA, Peterson LM, Petra PH, et al. Factors affecting the level and heterogeneity of uptake of (^{18}F) fluoroestradiol (FES) in patients with estrogen receptor positive (ER+) breast cancer. J Nucl Med 2002;43:286P.

120. Dehdashti F, Mortimer JE, Siegel BA, et al. Positron tomographic assessment of estrogen receptors in breast cancer: comparison with FDG-PET and *in vitro* receptor assays. J Nucl Med 1995;36:1766–74.

121. Mortimer JE, Dehdashti F, Siegel BA, et al. Positron emission tomography with 2-[^{18}F]fluoro-2-deoxy-D-glucose and 16α-[^{18}F]fluoro-17β-estradiol in breast cancer: correlation with estrogen receptor status and response to systemic therapy. Clin Cancer Res 1996;2:933–9.

122. Meyer JS, Wittliff JL. Regional heterogeneity in breast carcinoma: thymidine labelling index, steroid hormone receptors, DNA ploidy. Int J Cancer 1991;47:213–20.

123. Gutierrez MC, Detre S, Johnston S, et al. Molecular changes in tamoxifen-resistant breast cancer: relationship between estrogen receptor, HER-2, and p38 mitogen-activated protein kinase. J Clin Oncol 2005;23:2469–76.

124. Campbell FC, Blamey RW, Elston CW, et al. Quantitative oestradiol receptor values in primary breast cancer and response of metastases to endocrine therapy. Lancet 1981;2:1317–9.

125. Mortimer JE, Dehdashti F, Siegel BA, et al. Metabolic flare: indicator of hormone responsiveness in advanced breast cancer. J Clin Oncol 2001;19:2797–803.

126. Linden HM, Stekhova SA, Link JM, et al. HER2 expression and uptake of (18)F-fluoroestradiol (FES) predict response of breast cancer to hormonal therapy. J Nucl Med 2004;45:85P.

127. McGuire AH, Dehdashti F, Siegel BA, et al. Positron tomographic assessment of 16α-[^{18}F]fluoro-17β-estradiol uptake in metastatic breast carcinoma. J Nucl Med 1991;32:1526–31.

128. Dehdashti F, Flanagan FL, Mortimer JE, et al. Positron emission tomographic assessment of "metabolic flare" to predict response of metastatic breast cancer to antiestrogen therapy. Eur J Nucl Med 1999;26:51–6.

129. Osborne CK, Shou J, Massarweh S, et al. Crosstalk between estrogen receptor and growth factor receptor pathways as a cause for endocrine therapy resistance in breast cancer. Clin Cancer Res 2005;11:865–70s.

130. Scher HI, Heller G. Clinical states in prostate cancer: toward a dynamic model of disease progression. Urology 2000;55:323–7.

131. Bonasera TA, O'Neil JP, Xu M, et al. Preclinical evaluation of fluorine-18-labeled androgen receptor ligands in baboons. J Nucl Med 1996;37:1009–15.

132. Larson SM, Morris M, Gunther I, et al. Tumor localization of 16β-^{18}F-fluoro-5α-dihydrotestosterone versus ^{18}F-FDG in patients with progressive, metastatic prostate cancer. J Nucl Med 2004;45:366–73.

133. Zanzonico PB, Finn R, Pentlow KS, et al. PET-based radiation dosimetry in man of ^{18}F-fluorodihydrotestosterone, a new radiotracer for imaging prostate cancer. J Nucl Med 2004;45:1966–71.

134. Dehdashti F, Picus J, Michalski JM, et al. Positron tomographic assessment of androgen receptors in prostatic carcinoma. Eur J Nucl Med Mol Imaging 2005;32:344–50.

135. Ling V. Multidrug resistance: molecular mechanisms and clinical relevance. Cancer Chemother Pharmacol 1997;40 Suppl:S3–8.

136. Cole SP, Deeley RG. Multidrug resistance associated with overexpression of MRP. Cancer Treat Res 1996;87:39–62.

137. Baldini N, Scotlandi K, Serra M, et al. P-glycoprotein expression in osteosarcoma: a basis for risk-adapted adjuvant chemotherapy. J Orthop Res 1999;17:629–32.

138. Hendrikse NH, Bart J, de Vries EG, et al. P-glycoprotein at the blood-brain barrier and analysis of drug transport with positron-emission tomography. J Clin Pharmacol 2001;Suppl:48–54S.

139. Hendrikse NH, de Vries EG, Eriks-Fluks L, et al. A new *in vivo* method to study P-glycoprotein transport in tumors and the blood-brain barrier. Cancer Res 1999;59:2411–6.

140. Hendrikse NH, de Vries EG, Franssen EJ, et al. *In vivo* measurement of [^{11}C]verapamil kinetics in human tissues. Eur J Clin Pharmacol 2001;56:827–9.

141. Link JM, Unadkat JD, Muzi M, et al. *In vivo* P-glycoprotein (P-gp) transport activity in the pregnant macaque (*M. nemestrina*) as measured by biodistribution of ^{11}C-verapamil and PET. J Nucl Med 2002;43:277P.

142. Sasongko L, Link JM, Muzi M, et al. Imaging P-glycoprotein transport at the human blood-brain barrier using positron emission tomography. Clin Pharmacol Ther 2005;77:503–14.

143. Warner RR, O'Dorisio TM. Radiolabeled peptides in diagnosis and tumor imaging: clinical overview. Semin Nucl Med 2002;32:79–83.

144. Eberle AN, Mild G, Froidevaux S. Receptor-mediated tumor targeting with radiopeptides. Part 1. General concepts and methods: applications to somatostatin receptor-expressing tumors. J Recept Signal Transduct Res 2004;24:319–455.

145. Termanini B, Gibril F, Reynolds JC, et al. Value of somatostatin receptor scintigraphy: a prospective study in gastrinoma of its effect on clinical management. Gastroenterology 1997;112:335–47.

146. Helisch A, Forster GJ, Reber H, et al. Pre-therapeutic dosimetry and biodistribution of ^{86}Y-DOTA-Phe^{1}-Tyr^{3}-octreotide versus ^{111}In-pentetreotide in patients with advanced neuroendocrine tumours. Eur J Nucl Med Mol Imaging 2004;31:1386–92.

Downloaded from clincancerres.aacrjournals.org on April 5, 2013. © 2005 American Association for Cancer Research.

147. Goldenberg DM, DeLand F, Kim E, et al. Use of radiolabeled antibodies to carcinoembryonic antigen for the detection and localization of diverse cancers by external photoscanning. N Engl J Med 1978;298:1384–6.

148. Goldenberg DM, Juweid M, Dunn RM, et al. Cancer imaging with radiolabeled antibodies: new advances with technetium-99m-labeled monoclonal antibody Fab′ fragments, especially CEA-Scan and prospects for therapy. J Nucl Med Technol 1997;25:18–23; quiz 34.

149. East IJ, Keenan AM, Larson SM, et al. Scintigraphy of normal mouse ovaries with monoclonal antibodies to ZP-2, the major zona pellucida protein. Science 1984;225:938–41.

150. Larson SM, Carrasquillo JA, Reynolds JC. Radioimmunodetection and radioimmunotherapy. Cancer Invest 1984;2:363–81.

151. Pressman D. The development and use of radiolabeled antitumor antibodies. Cancer Res 1980;40:2960–4.

152. Lou Boucher Y, Baxter LT, Jain RK. Interstitial pressure gradients in tissue-isolated and subcutaneous tumors: implications for therapy. Cancer Res 1990;50:4478–84.

153. Press OW, Eary JF, Badger CC, et al. Treatment of refractory non-Hodgkin's lymphoma with radiolabeled MB-1 (anti-CD37) antibody. J Clin Oncol 1989;7:1027–38.

154. Kohler G, Milstein C. Continuous cultures of fused cells secreting antibody of predefined specificity. Nature 1975;256:495–7.

155. Co MS, Avdalovic NM, Caron PC, et al. Chimeric and humanized antibodies with specificity for the CD33 antigen. J Immunol 1992;148:1149–54.

156. Mach JP, Carrel S, Forni M, et al. Tumor localization of radiolabeled antibodies against carcinoembryonic antigen in patients with carcinoma: a critical evaluation. N Engl J Med 1980;303:5–10.

157. Larson SM, Carrasquillo JA, Krohn KA, et al. Localization of ^{131}I-labeled p97-specific Fab fragments in human melanoma as a basis for radiotherapy. J Clin Invest 1983;72:2101–14.

158. Moffat FL, Jr., Pinsky CM, Hammershaimb L, et al. Clinical utility of external immunoscintigraphy with the IMMU-4 technetium-99m Fab′antibody fragment in patients undergoing surgery for carcinoma of the colon and rectum: results of a pivotal, phase III trial. The Immunomedics Study Group. J Clin Oncol 1996;14:2295–305.

159. Patt YZ, Podoloff DA, Curley S, et al. Technetium 99m-labeled IMMU-4, a monoclonal antibody against carcinoembryonic antigen, for imaging of occult recurrent colorectal cancer in patients with rising serum carcinoembryonic antigen levels. J Clin Oncol 1994;12:489–95.

160. Willkomm P, Bender H, Bangard M, et al. FDG PET and immunoscintigraphy with ^{99m}Tc-labeled antibody fragments for detection of the recurrence of colorectal carcinoma. J Nucl Med 2000;41:1657–63.

161. Juweid M, Sharkey RM, Behr T, et al. Improved detection of medullary thyroid cancer with radiolabeled antibodies to carcinoembryonic antigen. J Clin Oncol 1996;14:1209–17.

162. Petronis JD, Regan F, Lin K. Indium-111 capromab pendetide (ProstaScint) imaging to detect recurrent and metastatic prostate cancer. Clin Nucl Med 1998;23:672–7.

163. Murphy GP, Elgamal AA, Troychak MJ, et al. Follow-up ProstaScint scans verify detection of occult soft-tissue recurrence after failure of primary prostate cancer therapy. Prostate 2000;42:315–7.

164. Sodee DB, Nelson AD, Faulhaber PF, et al. Update on fused capromab pendetide imaging of prostate cancer. Clin Prostate Cancer 2005;3:230–8.

165. Thomas CT, Bradshaw PT, Pollock BH, et al. Indium-111-capromab pendetide radioimmunoscintigraphy and prognosis for durable biochemical response to salvage radiation therapy in men after failed prostatectomy. J Clin Oncol 2003;21:1715–21.

166. Davis TA, Kaminski MS, Leonard JP, et al. The radioisotope contributes significantly to the activity of radioimmunotherapy. Clin Cancer Res 2004;10:7792–8.

167. Kaminski MS, Tuck M, Estes J, et al. ^{131}I-Tositumomab therapy as initial treatment for follicular lymphoma. N Engl J Med 2005;352:441–9.

168. Wiseman GA, Witzig TE. Yttrium-90 (^{90}Y) ibritumomab tiuxetan (Zevalin) induces long-term durable responses in patients with relapsed or refractory B-cell non-Hodgkin's lymphoma. Cancer Biother Radiopharm 2005;20:185–8.

169. Forero A, Weiden PL, Vose JM, et al. Phase 1 trial of a novel anti-CD20 fusion protein in pretargeted radioimmunotherapy for B-cell non-Hodgkin lymphoma. Blood 2004;104:227–36.

170. Sharkey RM, McBride WJ, Karacay H, et al. A universal pretargeting system for cancer detection and therapy using bispecific antibody. Cancer Res 2003;63:354–63.

171. He J, Liu G, Gupta S, et al. Amplification targeting: a modified pretargeting approach with potential for signal amplification-proof of a concept. J Nucl Med 2004;45:1087–95.

172. Ballou B, Fisher GW, Hakala TR, et al. Tumor detection and visualization using cyanine fluorochrome-labeled antibodies. Biotechnol Prog 1997;13:649–58.

173. Larson SM, Pentlow KS, Volkow ND, et al. PET scanning of iodine-124-3F9 as an approach to tumor dosimetry during treatment planning for radioimmunotherapy in a child with neuroblastoma. J Nucl Med 1992;33:2020–3.

174. Lovqvist A, Humm JL, Sheikh A, et al. PET imaging of (86)Y-labeled anti-Lewis Y monoclonal antibodies in a nude mouse model: comparison between (86)Y and (111)In radiolabels. J Nucl Med 2001;42:1281–7.

175. Olafsen T, Tan GJ, Cheung CW, et al. Characterization of engineered anti-p185HER-2 (scFv-CH3)2 antibody fragments (minibodies) for tumor targeting. Protein Eng Des Sel 2004;17:315–23.

176. Sundaresan G, Yazaki PJ, Shively JE, et al. ^{124}I-labeled engineered anti-CEA minibodies and diabodies allow high-contrast, antigen-specific small-animal PET imaging of xenografts in athymic mice. J Nucl Med 2003;44:1962–9.

177. Winter G, Harris WJ. Humanized antibodies. Immunol Today 1993;14:243–6.

178. Smith-Jones PM, Solit DB, Akhurst T, et al. Imaging the pharmacodynamics of HER2 degradation in response to Hsp90 inhibitors. Nat Biotechnol 2004;22:701–6.

179. Mulford DA, Scheinberg DA, Jurcic JG. The promise of targeted α-particle therapy. J Nucl Med 2005;46 Suppl 1:199–204S.

180. Jurcic JG, Larson SM, Sgouros G, et al. Targeted α particle immunotherapy for myeloid leukemia. Blood 2002;100:1233–9.

181. Grierson JR, Schwartz JL, Muzi M, et al. Metabolism of 3′-deoxy-3′-[F-18]fluorothymidine in proliferating A549 cells: validations for positron emission tomography. Nucl Med Biol 2004;31:829–37.

Downloaded from clincancerres.aacrjournals.org on April 5, 2013. © 2005 American Association for Cancer Research.